

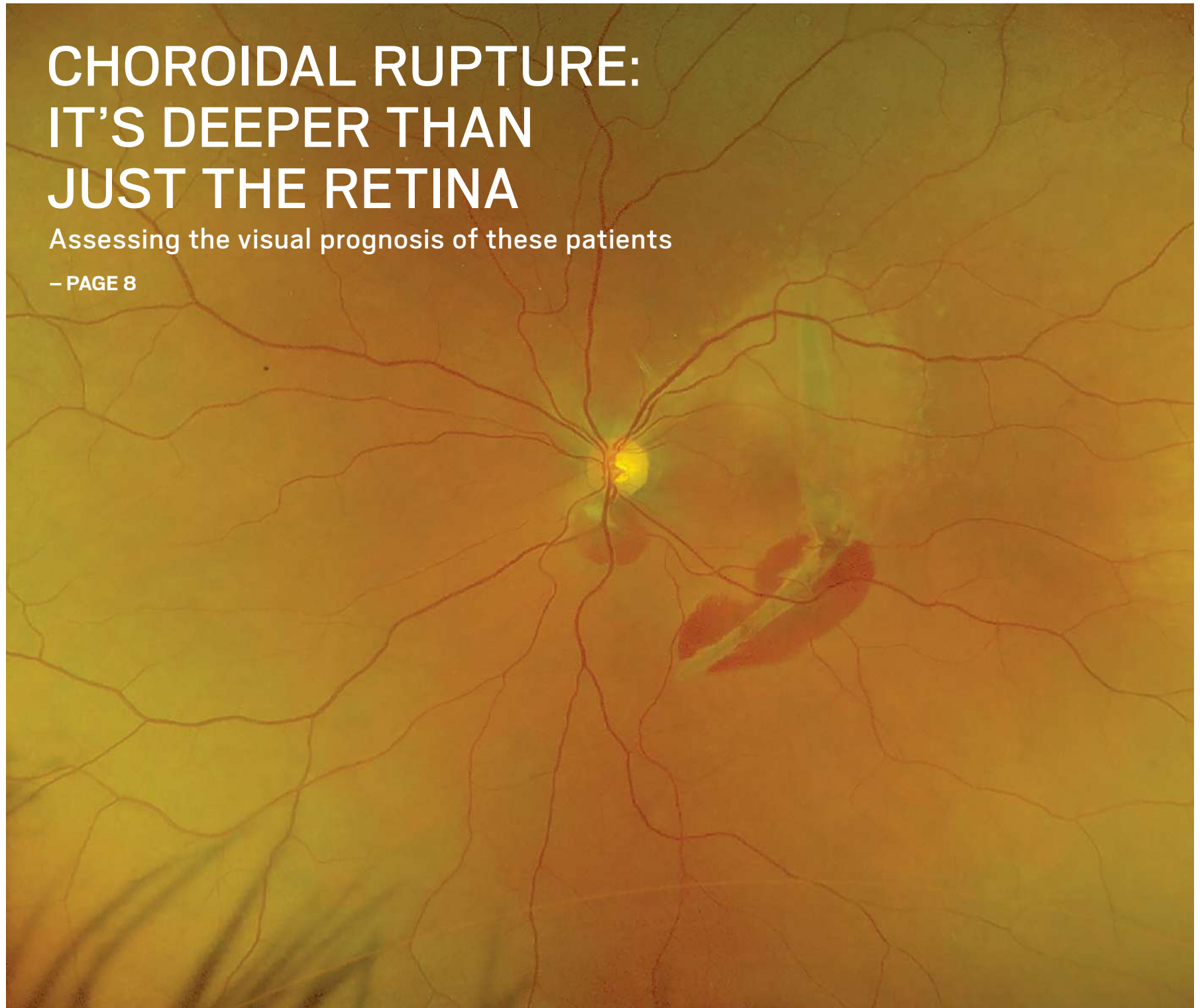
# New Retinal PHYSICIAN

CASE STUDIES AND CLINICAL PERSPECTIVES FOR THE EMERGENT RETINA SPECIALIST

## CHOROIDAL RUPTURE: IT'S DEEPER THAN JUST THE RETINA

Assessing the visual prognosis of these patients

– PAGE 8



### **SURGERY**

Suprachoroidal hemorrhages during cataract surgery

– PAGE 10

### **PREDICTING OUTCOMES**

Predicting outcomes following epiretinal membrane peeling surgery

– PAGE 13

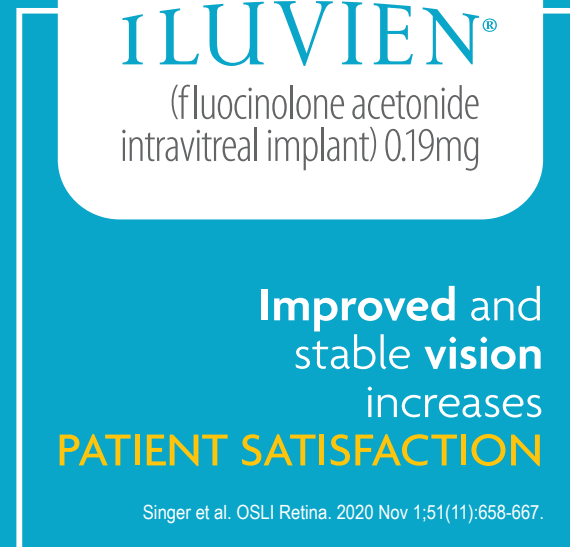
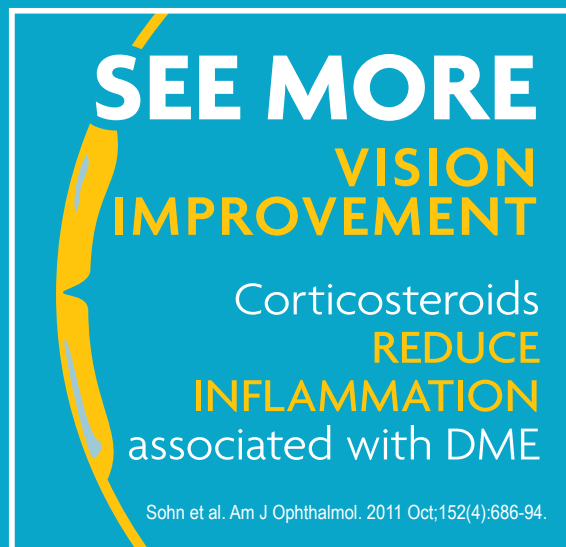
### **PFO REMOVAL**

Surgical techniques to remove subretinal perfluoro-n-octane

– PAGE 16

AN OFFICIAL  
PUBLICATION OF





## ILUVIEN is the most durable DME treatment providing up to 36 months of therapy

Learn more at [HCP.ILUVIEN.COM](http://HCP.ILUVIEN.COM)

### INDICATION

ILUVIEN<sup>®</sup> (fluocinolone acetonide intravitreal implant) 0.19 mg is indicated for the treatment of diabetic macular edema (DME) in patients who have been previously treated with a course of corticosteroids and did not have a clinically significant rise in intraocular pressure.

### Important Safety Information

#### CONTRAINDICATIONS

- ILUVIEN is contraindicated in patients with active or suspected ocular or periocular infections including most viral disease of the cornea and conjunctiva including active epithelial herpes simplex keratitis (dendritic keratitis), vaccinia, varicella, mycobacterial infections and fungal diseases.
- ILUVIEN is contraindicated in patients with glaucoma who have cup to disc ratios of greater than 0.8.
- ILUVIEN is contraindicated in patients with known hypersensitivity to any components of this product.

#### WARNINGS AND PRECAUTIONS

- Intravitreal injections, including those with ILUVIEN, have been associated with endophthalmitis, eye inflammation, increased intraocular pressure, and retinal detachments. Patients should be monitored following the intravitreal injection.
- Use of corticosteroids including ILUVIEN may produce posterior subcapsular cataracts, increased intraocular pressure and glaucoma. Use of corticosteroids may enhance the establishment of secondary ocular infections due to bacteria, fungi, or viruses. Corticosteroids are not recommended to be used in patients with a history of ocular herpes simplex because of the potential for reactivation of the viral infection.
- Patients in whom the posterior capsule of the lens is absent or has a tear are at risk of implant migration into the anterior chamber.

#### ADVERSE REACTIONS

- In controlled studies, the most common adverse reactions reported were cataract development (ILUVIEN 82%; sham 50%) and intraocular pressure elevation of  $\geq 10$  mm Hg (ILUVIEN 34%; sham 10%).

Please see Brief Summary of Full Prescribing Information on the following page.

You are encouraged to report negative side effects of prescription drugs to the FDA. Visit MedWatch or call 1-800-FDA-1088.

## BRIEF SUMMARY OF FULL PRESCRIBING INFORMATION

ILUVIEN® (fluocinolone acetonide intravitreal implant) 0.19 mg  
For Intravitreal Injection

### INDICATIONS AND USAGE

ILUVIEN® (fluocinolone acetonide intravitreal implant) 0.19 mg is indicated for the treatment of diabetic macular edema in patients who have been previously treated with a course of corticosteroids and did not have a clinically significant rise in intraocular pressure.

### CONTRAINDICATIONS

**Ocular or Periocular Infections:** ILUVIEN is contraindicated in patients with active or suspected ocular or periocular infections including most viral disease of the cornea and conjunctiva including active epithelial herpes simplex keratitis (dendritic keratitis), vaccinia, varicella, mycobacterial infections and fungal diseases.

**Glaucoma:** ILUVIEN is contraindicated in patients with glaucoma who have cup to disc ratios of greater than 0.8.

**Hypersensitivity:** ILUVIEN is contraindicated in patients with known hypersensitivity to any components of this product.

### WARNINGS AND PRECAUTIONS

**Intravitreal Injection-related Effects:** Intravitreal injections, including those with ILUVIEN, have been associated with endophthalmitis, eye inflammation, increased intraocular pressure, and retinal detachments. Patients should be monitored following the intravitreal injection.

**Steroid-related Effects:** Use of corticosteroids including ILUVIEN may produce posterior subcapsular cataracts, increased intraocular pressure and glaucoma. Use of corticosteroids may enhance the establishment of secondary ocular infections due to bacteria, fungi, or viruses.

Corticosteroids are not recommended to be used in patients with a history of ocular herpes simplex because of the potential for reactivation of the viral infection.

**Risk of Implant Migration:** Patients in whom the posterior capsule of the lens is absent or has a tear are at risk of implant migration into the anterior chamber.

### ADVERSE REACTIONS

**Clinical Studies Experience:** Because clinical trials are conducted under widely varying conditions, adverse reaction rates observed in the clinical trials of a drug cannot be directly compared to rates in the clinical trials of another drug and may not reflect the rates observed in practice.

Adverse reactions associated with ophthalmic steroids including ILUVIEN include cataract formation and subsequent cataract surgery, elevated intraocular pressure, which may be associated with optic nerve damage, visual acuity and field defects, secondary ocular infection from pathogens including herpes simplex, and perforation of the globe where there is thinning of the cornea or sclera.

ILUVIEN was studied in two multicenter, randomized, sham-controlled, masked trials in which patients with diabetic macular edema were treated with either ILUVIEN (n=375) or sham (n=185). Table 1 summarizes safety data available when the last subject completed the last 36-month follow-up visit for the two primary ILUVIEN trials. In these trials, subjects were eligible for retreatment no earlier than 12 months after study entry. Over the three-year follow-up period, approximately 75% of the ILUVIEN treated subjects received only one ILUVIEN implant.

Table 1: Ocular Adverse Reactions Reported by ≥1% of Patients and Non-ocular Adverse Reactions Reported by ≥5% of Patients

Adverse Reactions	ILUVIEN (N=375) n (%)	Sham (N=185) n (%)
<b>Ocular</b>		
Cataract <sup>1</sup>	192/235 <sup>2</sup> (82%)	61/121 <sup>2</sup> (50%)
Myodesopsia	80 (21%)	17 (9%)
Eye pain	57 (15%)	25 (14%)
Conjunctival haemorrhage	50 (13%)	21 (11%)
Posterior capsule opacification	35 (9%)	6 (3%)
Eye irritation	30 (8%)	11 (6%)
Vitreous detachment	26 (7%)	12 (7%)
Conjunctivitis	14 (4%)	5 (3%)
Corneal oedema	13 (4%)	3 (2%)
Foreign body sensation in eyes	12 (3%)	4 (2%)
Eye pruritus	10 (3%)	3 (2%)
Ocular hyperaemia	10 (3%)	3 (2%)
Optic atrophy	9 (2%)	2 (1%)
Ocular discomfort	8 (2%)	1 (1%)
Photophobia	7 (2%)	2 (1%)
Retinal exudates	7 (2%)	0 (0%)
Anterior chamber cell	6 (2%)	1 (1%)
Eye discharge	6 (2%)	1 (1%)

Table 1 (continued)

Adverse Reactions	ILUVIEN (N=375) n (%)	Sham (N=185) n (%)
<b>Non-ocular</b>		
Anemia	40 (11%)	10 (5%)
Headache	33 (9%)	11 (6%)
Renal failure	32 (9%)	10 (5%)
Pneumonia	28 (7%)	8 (4%)

<sup>1</sup> Includes cataract, cataract nuclear, cataract subcapsular, cataract cortical and cataract diabetic in patients who were phakic at baseline. Among these patients, 80% of ILUVIEN subjects vs. 27% of sham-controlled subjects underwent cataract surgery.

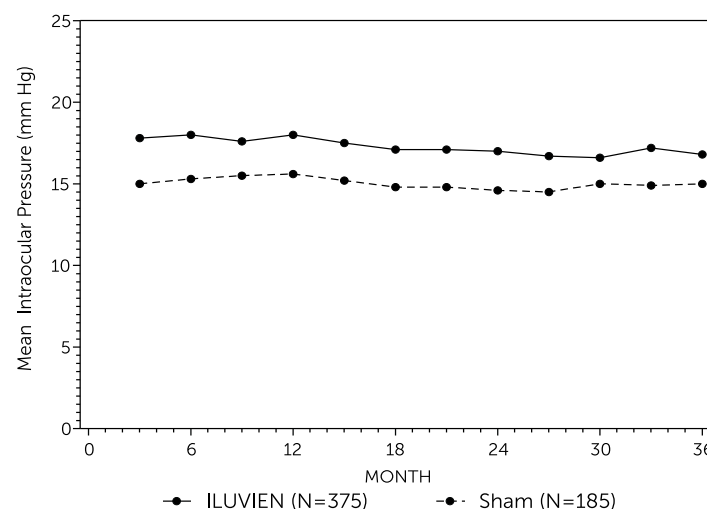
<sup>2</sup> 235 of the 375 ILUVIEN subjects were phakic at baseline; 121 of 185 sham-controlled subjects were phakic at baseline.

### Increased Intraocular Pressure

Table 2: Summary of Elevated IOP-Related Adverse Reactions

Event	ILUVIEN (N=375) n (%)	Sham (N=185) n (%)
<b>Non-ocular</b>		
IOP elevation ≥ 10 mm Hg from baseline	127 (34%)	18 (10%)
IOP elevation ≥ 30 mm Hg	75 (20%)	8 (4%)
Any IOP-lowering medication	144 (38%)	26 (14%)
Any surgical intervention for elevated intraocular pressure	18 (5%)	1 (1%)

Figure 1: Mean IOP during the study



### Cataracts and Cataract Surgery

At baseline, 235 of the 375 ILUVIEN subjects were phakic; 121 of 185 sham-controlled subjects were phakic. The incidence of cataract development in patients who had a phakic study eye was higher in the ILUVIEN group (82%) compared with sham (50%). The median time of cataract being reported as an adverse event was approximately 12 months in the ILUVIEN group and 19 months in the sham group. Among these patients, 80% of ILUVIEN subjects vs. 27% of sham-controlled subjects underwent cataract surgery, generally within the first 18 months (Median Month 15 for both ILUVIEN group and for sham) of the studies.

**Post-marketing Experience:** The following reactions have been identified during post-marketing use of ILUVIEN in clinical practice. Because they are reported voluntarily, estimates of frequency cannot be made. The reactions, which have been chosen for inclusion due to either their seriousness, frequency of reporting, possible causal connection to ILUVIEN, or a combination of these factors, include reports of drug administration error and reports of the drug being ineffective.

### USE IN SPECIFIC POPULATIONS

#### Pregnancy: Pregnancy Category C.

There are no adequate and well-controlled studies of ILUVIEN in pregnant women. Animal reproduction studies have not been conducted with fluocinolone acetonide. Corticosteroids have been shown to be teratogenic in laboratory animals when administered systemically at relatively low dosage levels. ILUVIEN should be used during pregnancy only if the potential benefit justifies the potential risk to the fetus.

**Nursing Mothers:** Systemically administered corticosteroids are present in human milk and could suppress growth and interfere with endogenous corticosteroid production. The systemic concentration of fluocinolone acetonide following intravitreal treatment with ILUVIEN is low. It is not known whether intravitreal treatment with ILUVIEN could result in sufficient systemic absorption to produce detectable quantities in human milk. Exercise caution when ILUVIEN is administered to a nursing woman.

**Pediatric Use:** Safety and effectiveness of ILUVIEN in pediatric patients have not been established.

**Geriatric Use:** No overall differences in safety or effectiveness have been observed between elderly and younger patients.





**EYLEA<sup>®</sup>**  
(aflibercept) Injection  
For Intravitreal Injection

**10**  
years  
& **COUNTING**

FDA approved November 2011



*Inspired by real patients with Wet AMD, MEfRVO, and DME.*

## **IMPORTANT SAFETY INFORMATION**

### **CONTRAINDICATIONS**

- EYLEA is contraindicated in patients with ocular or periocular infections, active intraocular inflammation, or known hypersensitivity to aflibercept or to any of the excipients in EYLEA.

### **WARNINGS AND PRECAUTIONS**

- Intravitreal injections, including those with EYLEA, have been associated with endophthalmitis and retinal detachments. Proper aseptic injection technique must always be used when administering EYLEA. Patients should be instructed to report any symptoms suggestive of endophthalmitis or retinal detachment without delay and should be managed appropriately. Intraocular inflammation has been reported with the use of EYLEA.
- Acute increases in intraocular pressure have been seen within 60 minutes of intravitreal injection, including with EYLEA. Sustained increases in intraocular pressure have also been reported after repeated intravitreal dosing with VEGF inhibitors. Intraocular pressure and the perfusion of the optic nerve head should be monitored and managed appropriately.
- There is a potential risk of arterial thromboembolic events (ATEs) following intravitreal use of VEGF inhibitors, including EYLEA. ATEs are defined as nonfatal stroke, nonfatal myocardial infarction, or vascular death (including deaths of unknown cause). The incidence of reported thromboembolic events in wet AMD studies during the first year was 1.8% (32 out of 1824) in the combined group of patients treated with EYLEA compared with 1.5% (9 out of 595) in patients treated with ranibizumab; through 96 weeks, the incidence was 3.3% (60 out of 1824) in the EYLEA group compared with 3.2% (19 out of 595) in the ranibizumab group. The incidence in the DME studies from baseline to week 52 was 3.3% (19 out of 578) in the combined group of patients treated with EYLEA compared with 2.8% (8 out of 287) in the control group; from baseline to week 100, the incidence was 6.4% (37 out of 578) in the combined group of patients treated with EYLEA compared with 4.2% (12 out of 287) in the control group. There were no reported thromboembolic events in the patients treated with EYLEA in the first six months of the RVO studies.

EYLEA and EYLEA4U are registered trademarks of Regeneron Pharmaceuticals, Inc.

**REGENERON<sup>®</sup>**

© 2021, Regeneron Pharmaceuticals, Inc. All rights reserved.  
777 Old Saw Mill River Road, Tarrytown, NY 10591

# EYLEA HAS 10 YEARS OF REAL-WORLD EXPERIENCE, HELPING YOU PROVIDE YOUR PATIENTS WITH...

- ▶▶▶ First-line efficacy and safety data across 8 clinical trials<sup>1</sup>
- ▶▶▶ Dosing flexibility across several FDA-approved indications<sup>1</sup>
- ▶▶▶ Broad first-line coverage and dedicated support with EYLEA4U<sup>®2</sup>

## #1 PRESCRIBED ANTI-VEGF FDA APPROVED FOR WET AMD, DME, AND MEFRVO\*

\*IBM Truven MarketScan data: number of injections administered from Q4 2018 through Q3 2019; Data on file.

- ▶▶▶ **>16 million** doses administered to
- ▶▶▶ **>1.3 million** eyes since launch (and counting)<sup>2</sup>

EXPLORE THE DATA AT [HCP.EYLEA.US](https://hcp.eylea.us)

anti-VEGF, anti-vascular endothelial growth factor.

### ADVERSE REACTIONS

- Serious adverse reactions related to the injection procedure have occurred in <0.1% of intravitreal injections with EYLEA including endophthalmitis and retinal detachment.
- The most common adverse reactions (≥5%) reported in patients receiving EYLEA were conjunctival hemorrhage, eye pain, cataract, vitreous detachment, vitreous floaters, and intraocular pressure increased.
- Patients may experience temporary visual disturbances after an intravitreal injection with EYLEA and the associated eye examinations. Advise patients not to drive or use machinery until visual function has recovered sufficiently.

### INDICATIONS

EYLEA<sup>®</sup> (aflibercept) Injection 2 mg (0.05 mL) is indicated for the treatment of patients with Neovascular (Wet) Age-related Macular Degeneration (AMD), Macular Edema following Retinal Vein Occlusion (RVO), Diabetic Macular Edema (DME), and Diabetic Retinopathy (DR).

Please see brief summary of the full Prescribing Information on the following page.

References: 1. EYLEA<sup>®</sup> (aflibercept) Injection full U.S. Prescribing Information. Regeneron Pharmaceuticals, Inc. June 2021. 2. Data on file. Regeneron Pharmaceuticals, Inc.



**BRIEF SUMMARY—Please see the EYLEA full Prescribing Information available on HCP.EYLEA.US for additional product information.**

## 1 INDICATIONS AND USAGE

EYLEA is a vascular endothelial growth factor (VEGF) inhibitor indicated for the treatment of patients with:

**Neovascular (Wet) Age-Related Macular Degeneration (AMD), Macular Edema Following Retinal Vein Occlusion (RVO), Diabetic Macular Edema (DME), Diabetic Retinopathy (DR).**

## 4 CONTRAINDICATIONS

### 4.1 Ocular or Periocular Infections

EYLEA is contraindicated in patients with ocular or periocular infections.

### 4.2 Active Intraocular Inflammation

EYLEA is contraindicated in patients with active intraocular inflammation.

### 4.3 Hypersensitivity

EYLEA is contraindicated in patients with known hypersensitivity to aflibercept or any of the excipients in EYLEA. Hypersensitivity reactions may manifest as rash, pruritus, urticaria, severe anaphylactic/anaphylactoid reactions, or severe intraocular inflammation.

## 5 WARNINGS AND PRECAUTIONS

### 5.1 Endophthalmitis and Retinal Detachments

Intravitreal injections, including those with EYLEA, have been associated with endophthalmitis and retinal detachments [see *Adverse Reactions (6.1)*]. Proper aseptic injection technique must always be used when administering EYLEA. Patients should be instructed to report any symptoms suggestive of endophthalmitis or retinal detachment without delay and should be managed appropriately [see *Patient Counseling Information (17)*].

### 5.2 Increase in Intraocular Pressure

Acute increases in intraocular pressure have been seen within 60 minutes of intravitreal injection, including with EYLEA [see *Adverse Reactions (6.1)*]. Sustained increases in intraocular pressure have also been reported after repeated intravitreal dosing with vascular endothelial growth factor (VEGF) inhibitors. Intraocular pressure and the perfusion of the optic nerve head should be monitored and managed appropriately.

### 5.3 Thromboembolic Events

There is a potential risk of arterial thromboembolic events (ATEs) following intravitreal use of VEGF inhibitors, including EYLEA. ATEs are defined as nonfatal stroke, nonfatal myocardial infarction, or vascular death (including deaths of unknown cause). The incidence of reported thromboembolic events in wet AMD studies during the first year was 1.8% (32 out of 1824) in the combined group of patients treated with EYLEA compared with 1.5% (9 out of 595) in patients treated with ranibizumab; through 96 weeks, the incidence was 3.3% (60 out of 1824) in the EYLEA group compared with 3.2% (19 out of 595) in the ranibizumab group. The incidence in the DME studies from baseline to week 52 was 3.3% (19 out of 578) in the combined group of patients treated with EYLEA compared with 2.8% (8 out of 287) in the control group; from baseline to week 100, the incidence was 6.4% (37 out of 578) in the combined group of patients treated with EYLEA compared with 4.2% (12 out of 287) in the control group. There were no reported thromboembolic events in the patients treated with EYLEA in the first six months of the RVO studies.

## 6 ADVERSE REACTIONS

The following potentially serious adverse reactions are described elsewhere in the labeling:

- Hypersensitivity [see *Contraindications (4.3)*]
- Endophthalmitis and retinal detachments [see *Warnings and Precautions (5.1)*]
- Increase in intraocular pressure [see *Warnings and Precautions (5.2)*]
- Thromboembolic events [see *Warnings and Precautions (5.3)*]

### 6.1 Clinical Trials Experience

Because clinical trials are conducted under widely varying conditions, adverse reaction rates observed in the clinical trials of a drug cannot be directly compared to rates in other clinical trials of the same or another drug and may not reflect the rates observed in practice.

A total of 2980 patients treated with EYLEA constituted the safety population in eight phase 3 studies. Among those, 2379 patients were treated with the recommended dose of 2 mg. Serious adverse reactions related to the injection procedure have occurred in <0.1% of intravitreal injections with EYLEA including endophthalmitis and retinal detachment. The most common adverse reactions ( $\geq 5\%$ ) reported in patients receiving EYLEA were conjunctival hemorrhage, eye pain, cataract, vitreous detachment, vitreous floaters, and intraocular pressure increased.

**Neovascular (Wet) Age-Related Macular Degeneration (AMD).** The data described below reflect exposure to EYLEA in 1824 patients with wet AMD, including 1223 patients treated with the 2-mg dose, in 2 double-masked, controlled clinical studies (VIEW1 and VIEW2) for 24 months (with active control in year 1).

Safety data observed in the EYLEA group in a 52-week, double-masked, Phase 2 study were consistent with these results.

**Table 1: Most Common Adverse Reactions ( $\geq 1\%$ ) in Wet AMD Studies**

Adverse Reactions	Baseline to Week 52		Baseline to Week 96	
	EYLEA (N=1824)	Active Control (ranibizumab) (N=595)	EYLEA (N=1824)	Control (ranibizumab) (N=595)
Conjunctival hemorrhage	25%	28%	27%	30%
Eye pain	9%	9%	10%	10%
Cataract	7%	7%	13%	10%
Vitreous detachment	6%	6%	8%	8%
Vitreous floaters	6%	7%	8%	10%
Intraocular pressure increased	5%	7%	7%	11%
Ocular hyperemia	4%	8%	5%	10%
Corneal epithelium defect	4%	5%	5%	6%
Detachment of the retinal pigment epithelium	3%	3%	5%	5%
Injection site pain	3%	3%	3%	4%
Foreign body sensation in eyes	3%	4%	4%	4%
Lacrimation increased	3%	1%	4%	2%
Vision blurred	2%	2%	4%	3%
Intraocular inflammation	2%	3%	3%	4%
Retinal pigment epithelium tear	2%	1%	2%	2%
Injection site hemorrhage	1%	2%	2%	2%
Eyelid edema	1%	2%	2%	3%
Corneal edema	1%	1%	1%	1%
Retinal detachment	<1%	<1%	1%	1%

Less common serious adverse reactions reported in <1% of the patients treated with EYLEA were hypersensitivity, retinal tear, and endophthalmitis.

**Macular Edema Following Retinal Vein Occlusion (RVO).** The data described below reflect 6 months exposure to EYLEA with a monthly 2 mg dose in 218 patients following central retinal vein occlusion (CRVO) in 2 clinical studies (COPERNICUS and GALILEO) and 91 patients following branch retinal vein occlusion (BRVO) in one clinical study (VIBRANT).

**Table 2: Most Common Adverse Reactions ( $\geq 1\%$ ) in RVO Studies**

Adverse Reactions	CRVO		BRVO	
	EYLEA (N=218)	Control (N=142)	EYLEA (N=91)	Control (N=92)
Eye pain	13%	5%	4%	5%
Conjunctival hemorrhage	12%	11%	20%	4%
Intraocular pressure increased	8%	6%	2%	0%
Corneal epithelium defect	5%	4%	2%	0%
Vitreous floaters	5%	1%	1%	0%
Ocular hyperemia	5%	3%	2%	2%
Foreign body sensation in eyes	3%	5%	3%	0%
Vitreous detachment	3%	4%	2%	0%
Lacrimation increased	3%	4%	3%	0%
Injection site pain	3%	1%	1%	0%
Vision blurred	1%	<1%	1%	1%
Intraocular inflammation	1%	1%	0%	0%
Cataract	<1%	1%	5%	0%
Eyelid edema	<1%	1%	1%	0%

Less common adverse reactions reported in <1% of the patients treated with EYLEA in the CRVO studies were corneal edema, retinal tear, hypersensitivity, and endophthalmitis.

**Diabetic Macular Edema (DME) and Diabetic Retinopathy (DR).** The data described below reflect exposure to EYLEA in 578 patients with DME treated with the 2-mg dose in 2 double-masked, controlled clinical studies (VIVID and VISTA) from baseline to week 52 and from baseline to week 100.

**Table 3: Most Common Adverse Reactions ( $\geq 1\%$ ) in DME Studies**

Adverse Reactions	Baseline to Week 52		Baseline to Week 100	
	EYLEA (N=578)	Control (N=287)	EYLEA (N=578)	Control (N=287)
Conjunctival hemorrhage	28%	17%	31%	21%
Eye pain	9%	6%	11%	9%
Cataract	8%	9%	19%	17%
Vitreous floaters	6%	3%	8%	6%
Corneal epithelium defect	5%	3%	7%	5%
Intraocular pressure increased	5%	3%	9%	5%
Ocular hyperemia	5%	6%	5%	6%
Vitreous detachment	3%	3%	8%	6%
Foreign body sensation in eyes	3%	3%	3%	3%
Lacrimation increased	3%	2%	4%	2%
Vision blurred	2%	2%	3%	4%
Intraocular inflammation	2%	<1%	3%	1%
Injection site pain	2%	<1%	2%	<1%
Eyelid edema	<1%	1%	2%	1%

Less common adverse reactions reported in <1% of the patients treated with EYLEA were hypersensitivity, retinal detachment, retinal tear, corneal edema, and injection site hemorrhage.

Safety data observed in 269 patients with nonproliferative diabetic retinopathy (NPDR) through week 52 in the PANORAMA trial were consistent with those seen in the phase 3 VIVID and VISTA trials (see Table 3 above).

### 6.2 Immunogenicity

As with all therapeutic proteins, there is a potential for an immune response in patients treated with EYLEA. The immunogenicity of EYLEA was evaluated in serum samples. The immunogenicity data reflect the percentage of patients whose test results were considered positive for antibodies to EYLEA in immunoassays. The detection of an immune response is highly dependent on the sensitivity and specificity of the assays used, sample handling, timing of sample collection, concomitant medications, and underlying disease. For these reasons, comparison of the incidence of antibodies to EYLEA with the incidence of antibodies to other products may be misleading.

In the wet AMD, RVO, and DME studies, the pre-treatment incidence of immunoreactivity to EYLEA was approximately 1% to 3% across treatment groups. After dosing with EYLEA for 24-100 weeks, antibodies to EYLEA were detected in a similar percentage range of patients. There were no differences in efficacy or safety between patients with or without immunoreactivity.

## 8 USE IN SPECIFIC POPULATIONS

### 8.1 Pregnancy

#### Risk Summary

Adequate and well-controlled studies with EYLEA have not been conducted in pregnant women. Aflibercept produced adverse embryofetal effects in rabbits, including external, visceral, and skeletal malformations. A fetal No Observed Adverse Effect Level (NOAEL) was not identified. At the lowest dose shown to produce adverse embryofetal effects, systemic exposures (based on AUC for free aflibercept) were approximately 6 times higher than AUC values observed in humans after a single intravitreal treatment at the recommended clinical dose [see *Animal Data*].

Animal reproduction studies are not always predictive of human response, and it is not known whether EYLEA can cause fetal harm when administered to a pregnant woman. Based on the anti-VEGF mechanism of action for aflibercept, treatment with EYLEA may pose a risk to human embryofetal development. EYLEA should be used during pregnancy only if the potential benefit justifies the potential risk to the fetus.

All pregnancies have a background risk of birth defect, loss, or other adverse outcomes. The background risk of major birth defects and miscarriage for the indicated population is unknown. In the U.S. general population, the estimated background risk of major birth defects and miscarriage in clinically recognized pregnancies is 2-4% and 15-20%, respectively.

#### Data

##### Animal Data

In two embryofetal development studies, aflibercept produced adverse embryofetal effects when administered every three days during organogenesis to pregnant rabbits at intravenous doses  $\geq 3$  mg per kg, or every six days during organogenesis at subcutaneous doses  $\geq 0.1$  mg per kg.

Adverse embryofetal effects included increased incidences of postimplantation loss and fetal malformations, including anasarca, umbilical hernia, diaphragmatic hernia, gastroschisis, cleft palate, ectrodactyly, intestinal atresia, spina bifida, encephalomeningocele, heart and major vessel defects, and skeletal malformations (fused vertebrae, sternebrae, and ribs; supernumerary vertebral arches and ribs; and incomplete ossification). The maternal No Observed Adverse Effect Level (NOAEL) in these studies was 3 mg per kg. Aflibercept produced fetal malformations at all doses assessed in rabbits and the fetal NOAEL was not identified. At the lowest dose shown to produce adverse embryofetal effects in rabbits (0.1 mg per kg), systemic exposure (AUC) of free aflibercept was approximately 6 times higher than systemic exposure (AUC) observed in humans after a single intravitreal dose of 2 mg.

### 8.2 Lactation

#### Risk Summary

There is no information regarding the presence of aflibercept in human milk, the effects of the drug on the breastfed infant, or the effects of the drug on milk production/excretion. Because many drugs are excreted in human milk, and because the potential for absorption and harm to infant growth and development exists, EYLEA is not recommended during breastfeeding. The developmental and health benefits of breastfeeding should be considered along with the mother's clinical need for EYLEA and any potential adverse effects on the breastfed child from EYLEA.

### 8.3 Females and Males of Reproductive Potential

#### Contraception

Females of reproductive potential are advised to use effective contraception prior to the initial dose, during treatment, and for at least 3 months after the last intravitreal injection of EYLEA.

#### Infertility

There are no data regarding the effects of EYLEA on human fertility. Aflibercept adversely affected female and male reproductive systems in cynomolgus monkeys when administered by intravenous injection at a dose approximately 1500 times higher than the systemic level observed in humans with an intravitreal dose of 2 mg. A No Observed Adverse Effect Level (NOAEL) was not identified. These findings were reversible within 20 weeks after cessation of treatment.

### 8.4 Pediatric Use

The safety and effectiveness of EYLEA in pediatric patients have not been established.

### 8.5 Geriatric Use

In the clinical studies, approximately 76% (2049/2701) of patients randomized to treatment with EYLEA were  $\geq 65$  years of age and approximately 46% (1250/2701) were  $\geq 75$  years of age. No significant differences in efficacy or safety were seen with increasing age in these studies.

## 17 PATIENT COUNSELING INFORMATION

In the days following EYLEA administration, patients are at risk of developing endophthalmitis or retinal detachment. If the eye becomes red, sensitive to light, painful, or develops a change in vision, advise patients to seek immediate care from an ophthalmologist [see *Warnings and Precautions (5.1)*]. Patients may experience temporary visual disturbances after an intravitreal injection with EYLEA and the associated eye examinations [see *Adverse Reactions (6)*]. Advise patients not to drive or use machinery until visual function has recovered sufficiently.

# REGENERON

Manufactured by:  
**Regeneron Pharmaceuticals, Inc.**  
777 Old Saw Mill River Road  
Tarrytown, NY 10591

Issue Date: 08/2019  
Initial U.S. Approval: 2011

Based on the August 2019  
EYLEA® (aflibercept) Injection full  
Prescribing Information.

EYL.20.09.0052

EYLEA is a registered trademark of Regeneron Pharmaceuticals, Inc.  
© 2020, Regeneron Pharmaceuticals, Inc.  
All rights reserved.



## CHIEF MEDICAL EDITORS

Hemang K. Pandya, MD  
Mitul Mehta, MD, MS

## EXECUTIVE VICE PRESIDENT AND PUBLISHER

Douglas A. Parry  
doug.parry@pentavisionmedia.com • 215-694-7756

## SPECIAL PROJECTS

Alicia Isenberg • Director  
Susan Tarrant • Manager  
Courtney Tychinski • Editor

## DESIGN AND PRODUCTION

Sandra Kaden • Production Director  
William Pfaff • Senior Art Director

## PENTAVISION LIVE!

Abigail Markward • National Director  
abby.markward@pentavisionmedia.com • 949-636-0900

## eMEDIA

Megan Post • eMedia Production Director  
Emma D'Anjolell • eMedia Production Manager  
Jason Conaway • Database Administrator & Audience Development Associate  
Andrew Graf • Senior Digital Media Specialist  
Michael Brown-DiFalco • Digital Media & Data Specialist  
Sydney Lynch • Social Media Coordinator

## VIDEO TEAM

Adam Black • Director of Video & Webinar Services  
Travis Lowell • Video Editor

## DIGITAL MARKETING

Mindy Crawford • Director of Digital Marketing & Business Development  
Jakki O'Dowd • Digital Marketing Associate

## SOCIAL MEDIA

Mark Durrick • Chief Revenue Officer, Social Media  
Erinn Morgan • Director, Social Media  
Erica Hochman • Social Media Manager

## BUSINESS STAFF

Amy Wauhup • Marketing Manager  
Margaret Wehmeyer • Marketing Events Manager & Webinar Producer  
Margaret.wehmeyer@pentavisionmedia.com • 215-779-3746  
Carrie Eisenhandler • Circulation Manager  
Subscription inquiries/address changes • 847-763-9139 • rpm@omeda.com

## PRODUCTION AND EDITORIAL OFFICES

2003 South Easton Road, Suite 203, Doylestown, PA 18901 • 267-492-5200

## BUSINESS STAFF

Cheryl Brown • Eastern Region Account Manager  
cheryl.brown@pentavisionmedia.com • 215-534-6866  
Abigail Markward • Western Region Account Manager  
abby.markward@pentavisionmedia.com • 949-636-0900  
Meredith K. Styer • Business Manager  
meredith.styer@pentavisionmedia.com • 215-779-3746  
Barbara Kelly • Director of Sales Support  
barbara.kelly@pentavisionmedia.com • 973-223-0168  
Molly Bleil • Account Services Representative  
molly.bleil@pentavisionmedia.com • 215-605-3551  
Nicholas Vielhauer • Account Services Representative  
nicholas.vielhauer@pentavisionmedia.com • 267-492-5217

## CONFERENCE GROUP

Maureen Trusky, CMP • Conference Director  
maureen.trusky@pentavisionmedia.com • 215-514-3729  
Laura Shepherd • Conference Coordinator  
laura.shepherd@pentavisionmedia.com • 215-251-4127  
Julia McNamee • Director of Digital Events  
julia.mcnamee@pentavisionmedia.com • 215-431-6569  
Chelsea-Mia Pierre • Digital Events Associate  
chelseamia.pierre@pentavisionmedia.com • 267-218-6946

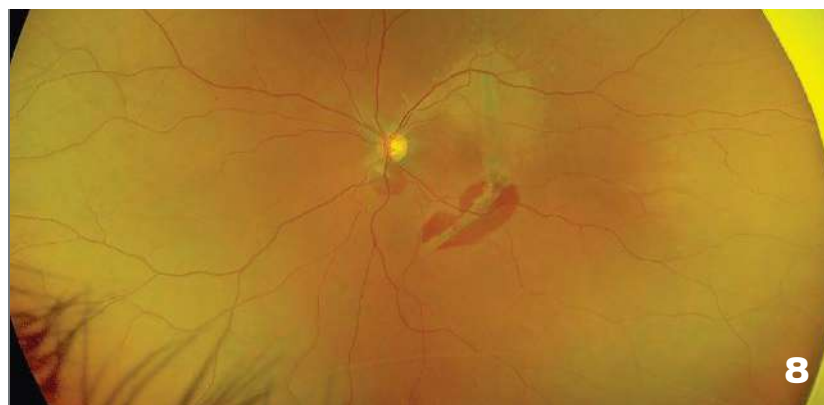
# PentaVision

President Thomas J. Wilson  
Executive Vice President, Ophthalmology Douglas Parry  
Executive Vice President, Optometry &  
Chief Revenue Officer, Social Media Mark Durrick  
Executive Vice President, eMedia Robert Verna

New Retinal Physician is published by PentaVision LLC.  
Copyright 2021, PentaVision LLC. All Rights Reserved.

# Table of Contents

NEW RETINAL PHYSICIAN



## FEATURES

### 8 CHOROIDAL RUPTURE

It's deeper than just the retina

By Hemang K. Pandya, MD, FACS

### 10 SUPRACHOROIDAL HEMORRHAGES DURING CATARACT SURGERY

Is surgical intervention the only treatment option?

By Wei Chen Lai, BS; Michael J. Elman, MD; Sidney A. Schechet, MD

### 13 PREDICTING OUTCOMES FOLLOWING EPIRETINAL MEMBRANE PEELING SURGERY

Macular anatomy may provide a clue to surgical outcomes

By Zack Oakey, MD

### 16 SURGICAL TECHNIQUES TO REMOVE SUBRETINAL PERFLUORO-n-OCTANE

An examination of benefits and risks

By Raziye Mahmoudzadeh, MD; Samir Patel, MD;

Carl D. Regillo, MD; Donald J., D'Amico, MD; Ajay E. Kuriyan, MD, MS

## DEPARTMENTS

### 6 FROM THE EDITOR

### 18 PRACTICE MANAGEMENT STRATEGIES

AN OFFICIAL PUBLICATION OF



New Retinal Physician is the official publication of the **American Retina Forum** (ARF). The ARF is a retina specialist community that facilitates learning from each other to improve patient care. This includes the sharing of case studies, clinical perspectives, and difficult case experiences. The ARF has nearly 650 members—with the majority of members having been in practice 15 years or fewer.

Cover image captured with an Optos California (courtesy of Hemang K. Pandya, MD, FACS).



# A Return to Meetings

**A**t this point, the overwhelming majority of physicians in the United States have been vaccinated against COVID-19, with most of us having 2—and for some, 3—doses of the mRNA vaccines that appear to be very effective against even the newer variants of the virus (as of the writing of this article). But, when will we physicians feel comfortable returning to traveling for meetings? I write this having just returned from the American Society of Retina Specialists (ASRS) meeting, and with the annual American Academy of Ophthalmology meeting a few short weeks away.

Many people are concerned, because both meetings draw a substantial cohort of people from around the world, where different vaccines are available (and in limited quantities). Prior to ASRS, there was significantly less buzz about attending the meeting, in part because of the location being outside of a major city, and partly because of COVID-19 fears.

Prior to ASRS, there was a smaller entrepreneurship meeting called OIS (Ophthalmology Innovation Summit). Historically, this was a great networking meeting with a lot of buzz, people having side conversations, and a few companies presenting in hopes of attracting funding or partnerships. This year, there was very little side conversation—and even less mask-wearing. I was personally shocked that almost no one was wearing a mask. I am triple-dosed with an mRNA vaccine, and I got my flu shot a week before I got on the plane. Still, I was nervous. There was no checking of vaccination status at this meeting either.

ASRS, on the other hand, seemed to take COVID-19 more seriously. Vaccination was

required and proof, using an app, was very easy. There were color-coded stickers that attendees could put on their name badges to alert others of their social distance request. Most people wore a mask most of the time when in the lecture hall, but definitely not at the lobby bar or restaurants.

At my practice at the University of California, Irvine, there is no way I would get away with this level of laxity in my clinics. ASRS was a much smaller meeting than it normally is, with fewer international attendees. I had fun, I learned about new therapies, and it was nice to hug my friends again. However, that comfort was yanked away when we received an email from the ASRS that an attendee had tested positive for COVID-19.

I'm confident that, at some point, the world will return back to normal, and I look forward to how open and collegial ophthalmology and retina is worldwide. Going to meetings in person is one of my favorite things to do. It's one thing to discuss cases over social media, but nothing can replace sitting down next to someone, sharing a meal or beverage, and talking about nonsense with some medicine mixed in.

With that in mind, the executive committee of the American Retina Forum is working with the Puerto Rico Society of Ophthalmology to have our largest live meeting ever, from June 29 to July 3, 2022 at the Wyndham Rio Mar in Puerto Rico. This will be a fun meeting where we do not take ourselves too seriously, but will get down to the details of how we take care of our patients. This is a collaborative meeting that has no suits or podiums, just an open discussion with short presentations to stimulate conversation.

We hope you join us. For more details, visit [www.retinaforum.org](http://www.retinaforum.org). **NRP**



**MITUL MEHTA, MD, MS**, is a clinical associate professor of ophthalmology in the retina division and is the fellowship director of vitreoretinal surgery at the Gavin Herbert Eye Institute of the University of California, Irvine.



IVERIC  
BIO

TRANSFORMATIVE  
THERAPIES  
FOR RETINAL DISEASES

---

Retina is our focus. **Our only focus.**

Geographic Atrophy | Stargardt Disease | Inherited Retinal Diseases

Learn more at [IvericBio.com](https://IvericBio.com)

# Choroidal Rupture

It's deeper than just the retina

BY HEMANG K. PANDYA, MD, FACS

**V**iolence has no place in our society. Let's start with that. According to the Centers for Disease Control (CDC), 20% of women report being victims of severe physical violence from an intimate partner.<sup>1</sup>

The coronavirus disease 2019 (COVID-19) started in China in late December of 2019 and has spread to the entire world, with approximately 4.5 million (and counting) deaths.<sup>2</sup> In response to this, many governments adopted quarantines, social distancing, travel restrictions, and stay-at-home orders. Emerging data show that since the outbreak of COVID-19, reports of domestic abuse have increased both nationally and internationally.<sup>3,4</sup> Many victims of abuse were forced to live with their abusers and had—and still have—limited access to supportive social resources.<sup>5</sup>

It's not out of the realm of possibility that such abuse will present itself in your office. The following case report, for example, sheds light on how domestic violence can result in permanent vision loss. While the particular diagnosis in question is an important feature of this patient's presentation, it is notable that the medical doctor has a fundamental duty to care for this patient in her entirety. Ophthalmologists and vitreoretinal surgeons are medical doctors first—and hold a responsibility to ensure that patients such

as this are safe. Once such arguably more important elements are adequately addressed, the particular question in the retina is considered.

## HISTORY AND CASE PRESENTATION

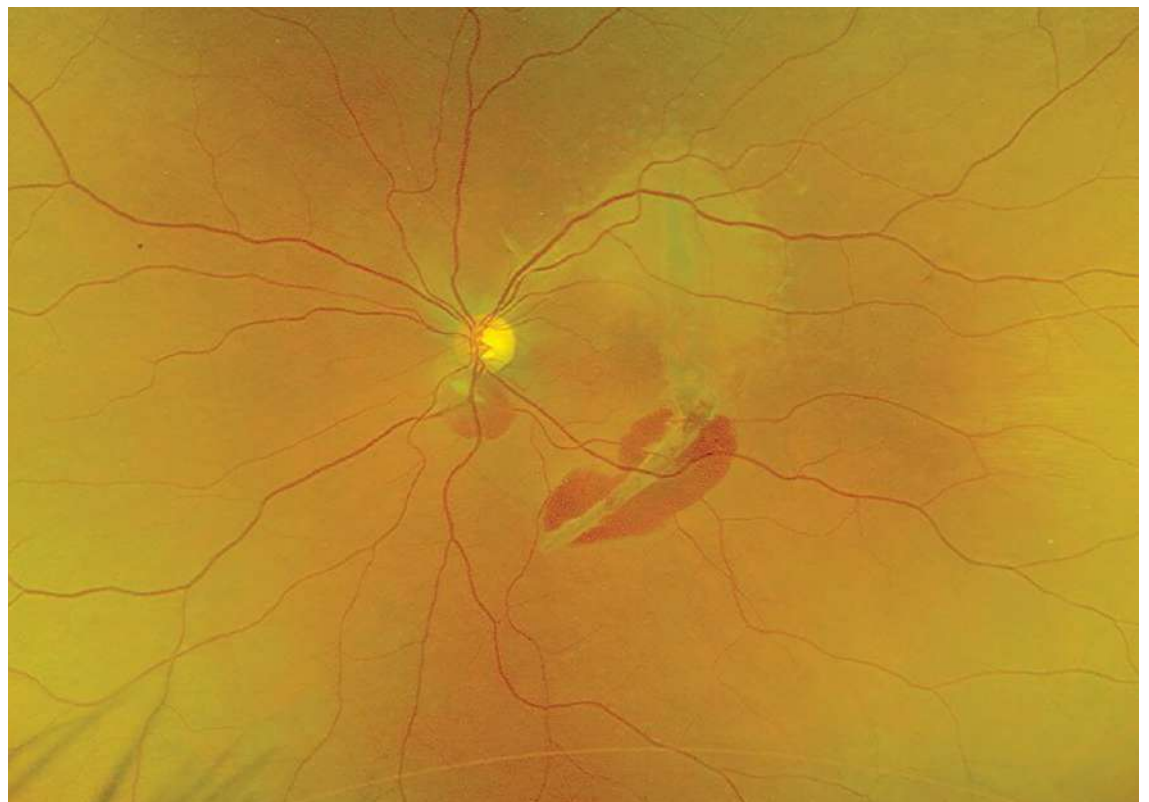
This patient is 38-year-old female who was recently a victim of domestic abuse. She noted decreased vision after fist-related facial trauma in the left eye. Her measured visual acuity was an eccentric 20/200. On dilated fundus exam, there was a white/yellow crescent-shaped subretinal lesion involving the fovea as well as subretinal blood both within the lesion and near the disc (**Figure 1**). Optical coherence tomography (OCT) showed disruption of the outer

retinal layers, Bruch's membrane, and retinal pigment epithelium (RPE) with extension into the choroidal layers in the right eye (**Figure 2**). Unfortunately, this patient has developed traumatic choroidal rupture.

## DISCUSSION

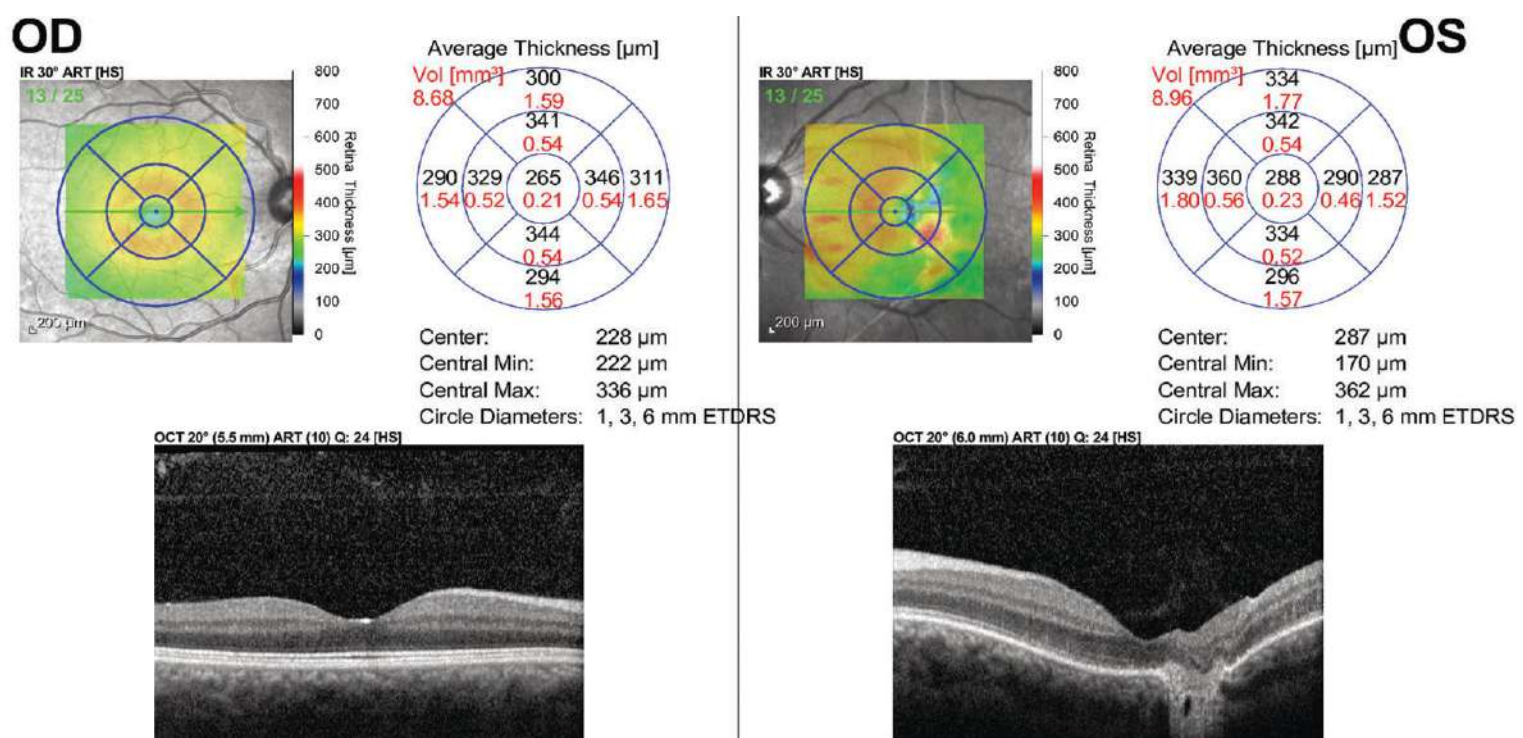
Choroidal rupture was first described by Dr. Albrecht von Graefe in 1854. It involves a break in the choroid, Bruch's membrane, and the RPE.

This diagnosis is made based on the history of a globe injury with a crescent-shaped white/yellow subretinal lesion concentric to the optic disc. Subretinal and sub-RPE hemorrhage can result at the time the choroidal rupture develops. This usually occurs secondary to blunt or



**FIGURE 1:** Color fundus photography revealed a choroidal rupture with adjacent subretinal hemorrhage in the posterior pole of the left eye.





**FIGURE 2:** OCT showed disruption of the outer retinal layers, Bruch's membrane, and retinal pigment epithelium (RPE) with extension into the choroidal layers in the right eye.

penetrating ocular injury. Some have classified this finding as a result of direct or indirect accelerating compression/decompression. A direct choroidal rupture occurs anteriorly at the site of impact, generally parallel to the ora serrata and peripheral retina. In contrast, an indirect choroidal rupture occurs away from the site of impact, more posterior, and often concentric to the optic disc in a crescent shape.

An overwhelming majority (approximately 80%) of choroidal ruptures are indirect.<sup>6</sup> Studies have found up to 5% to 10% of cases of blunt ocular trauma result in choroidal rupture.<sup>6</sup> This includes sports injuries from projectiles, such as tennis balls, soccer balls, or hockey pucks,<sup>7</sup> and even more diffuse injuries from air-bag deployment in motor vehicle accidents.<sup>8</sup>

The force buckles the globe in the area of impact and causes stress folding of the globe wall at a peripheral site, causing the choroid, RPE, and Bruch's membrane complex to stretch and break. This can be more

pronounced in those patients with brittle Bruch's membranes, such as Ehlers-Danlos syndrome or angioid streaks, where minimal trauma can result in choroidal rupture.

The visual prognosis of these patients is based on the initial visual acuity and concurrent traumatic optic neuropathy. Of note, given the associated globe trauma, it is of paramount importance to rule out any orbital bone injury or retinal dialysis.

## CONCLUSION

Given the imminent danger of residing within the home of her abuser, our patient has moved away from this region; therefore, there are no follow-up images to report. Since these patients are at high risk of choroidal neovascularization, she was given an Amsler grid and instructed to call should her vision change.

As retina specialists, we cannot forget our ethical duties as physicians and must always advocate for our patients, especially those patients in vulnerable situations. We pray that another similar case report is

never reported again. Unfortunately, the likelihood of that would take a miracle. **NRP**

## REFERENCES

- Centers for Disease Control and Prevention. What is intimate partner violence. Available at: <https://www.cdc.gov/violenceprevention/intimatepartnerviolence/fastfact.html>. Last accessed Oct. 8, 2021.
- World Health Organization. Coronavirus disease (COVID-19) situation Report – 190. Available at [https://www.who.int/docs/default-source/coronaviruse/situation-reports/20200728-covid-19-sitrep-190.pdf?sfvrsn=fec17314\\_2](https://www.who.int/docs/default-source/coronaviruse/situation-reports/20200728-covid-19-sitrep-190.pdf?sfvrsn=fec17314_2). Last accessed Oct. 8, 2021.
- Boserup B, McKenney M, Elkbuli A. Alarming trends in US domestic violence during the COVID-19 pandemic. *Am J Emerg Med.* 2020;38(12):2753-2755.
- United Nations UN News. UN chief calls for domestic violence 'ceasefire' amid 'horrifying global surge.' Available at: <https://news.un.org/en/story/2020/04/1061052>. Last accessed Oct. 8, 2021.
- Usher K, Bhullar N, Durkin J, Gyamfi N, Jackson D. Family violence and COVID-19: increased vulnerability and reduced options for support. *Int J Ment Health Nurs.* 2020;May 7:10.
- Williams DF, Mieler WF, Williams GA. Posterior segment manifestations of ocular trauma. *Retina.* 1990;10 Suppl:S35-S44.
- Morris DS. Ocular blunt trauma: loss of sight from an ice hockey injury. *Br J Sports Med.* 2006;40(3):e5.
- Wang SH, Lim CC, Teng YT. Airbag-associated severe blunt eye injury causes choroidal rupture and retinal hemorrhage: a case report. *Case Rep Ophthalmol.* 2017;8(1):13-20.

**DR. PANDYA** is president and a vitreoretinal surgeon at Dallas Retina Center in Plano, TX. He reports no related conflicts of interest. He can be reached at [DrPandya@DallasRetina.com](mailto:DrPandya@DallasRetina.com).



# Suprachoroidal Hemorrhages During Cataract Surgery

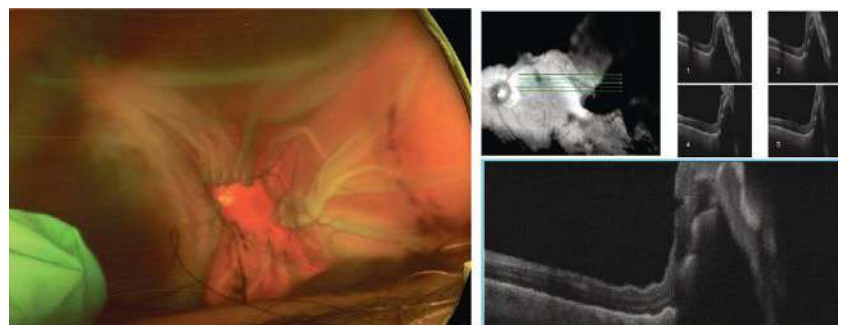
Is surgical intervention the only treatment option?

BY WEI CHEN LAI, BS; MICHAEL J. ELMAN, MD; AND SIDNEY A. SCHECHET, MD

**S**uprachoroidal hemorrhage (SCH) is a rare but devastating complication associated with incisional intraocular surgery as well as trauma.<sup>1</sup> Characterized as a sudden and rapid accumulation of blood within the suprachoroidal space, SCH can often result in severe, painful loss of vision.<sup>2</sup> It is believed that sudden intraocular pressure (IOP) fluctuation and/or hypotony cause the posterior long or short ciliary arteries to rupture, leading to the devastating bleed, although this is unclear.<sup>1,2</sup> Numerous risk factors for SCH have been well documented, including systemic factors, such as advanced age, hypertension, peripheral vascular disease, or antiplatelets/anticoagulation medications.<sup>2</sup>

Ocular risk factors leading to SCH development include high myopia, glaucoma, aphakia, pseudophakia, or previous intraocular surgery.<sup>3</sup> Intraoperatively, SCH can manifest as a complication of retrobulbar anesthesia, elevated IOP, Valsalva maneuvers (i.e., coughing, bucking, straining, etc.), hypertension, general anesthesia, and so on. Postoperatively, hypotony and Valsalva maneuvers can trigger SCH. Although SCH is associated with various ocular procedures, including cataract surgery, glaucoma filtering procedures, keratoplasty, and vitreoretinal surgery, this article will focus more on phaco-related choroidal hemorrhages and their management, but the lessons herein can be applied to most SCH scenarios.<sup>3</sup>

The incidence of SCH during or after cataract surgery is reported to range from 0.03% to 0.1% throughout the past 25 years, compared with 0.8%<sup>1</sup> with older techniques.<sup>4</sup> SCH is diagnosed clinically by sudden signs of severe ocular pain, a looming shadow progressively darkening the red reflex, shallowing of the anterior chamber, decreased vision, elevated IOP, and a firm globe.<sup>5</sup> Poor prognostic factors include SCH encompassing most/all 360 degrees, extracapsular cataract surgery, posterior capsule rupture



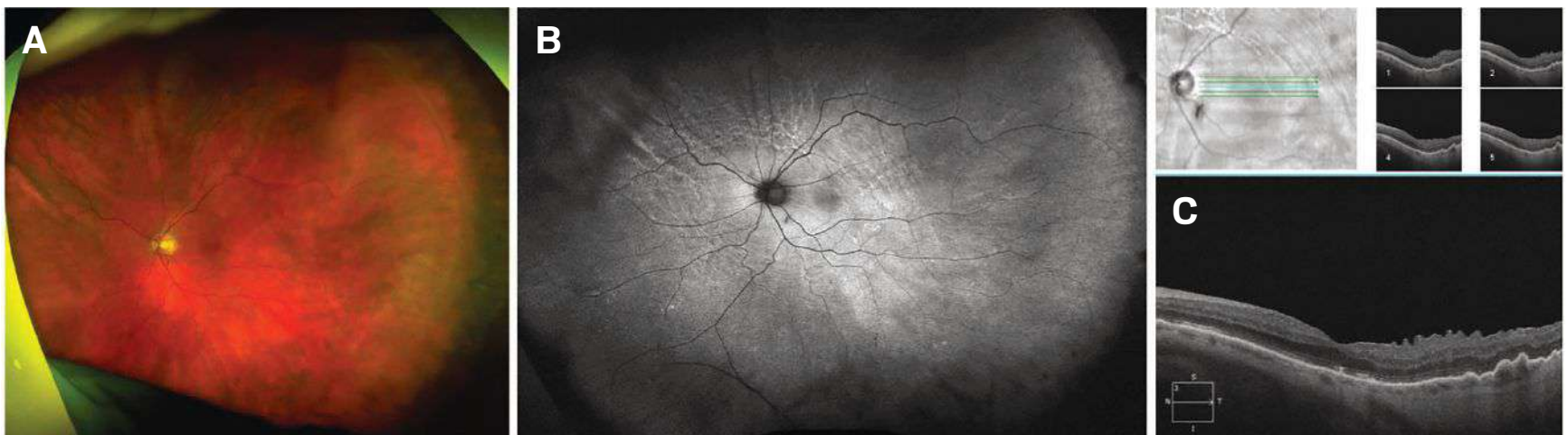**FIGURE 1:** Color fundus photo of left eye on presentation showing large non-kissing hemorrhagic choroidals with flat, corrugated retina; OCT 5-line raster scan of left eye on presentation with a flat retina but with choroidal detachment into the macula involving the fovea.

during phacoemulsification, retinal apposition (“kissing choroidals”), and retinal detachment.<sup>6-8</sup> As SCH remains a serious complication leading to significant visual loss, urgent diagnosis and management, including early detection, close monitoring of symptoms, and appropriate medical and/or surgical procedures, help maximize the chances of visual recovery.

In terms of treatment options, which will be discussed below, classic teaching advocates for surgical intervention in 1 to 2 weeks, as this is typically when liquefaction of the clotted hemorrhage occurs.<sup>7</sup> However, is surgery always necessary? The following two SCH cases illustrate great outcomes with conservative, nonoperative management.

## CASE EXAMPLE 1

A 75-year-old male with hypertension and chronic naproxen use was seen in the retina clinic 2 days after undergoing complex phacoemulsification complicated by suprachoroidal hemorrhage OS near the end of the case. The case was complicated by zonular instability needing a CTR-ring, posterior capsular rupture after IOL implantation, CTR and IOL explantation, anterior vitrectomy, and SCH occurring near the end of the case. On presentation, the patient had left eye pain, hand motion visual acuity,



**FIGURE 2:** Multimodal imaging of the left eye at post-op year one visit: (A) Optos color fundus photo; (B) Optos autofluorescence revealing all the past resolved/resolving choroidal fold lines; (C) OCT 5-line raster scan of the macula depicting a flat macula with mild ERM, resolving ellipsoid zone changes, and choroidal folds.

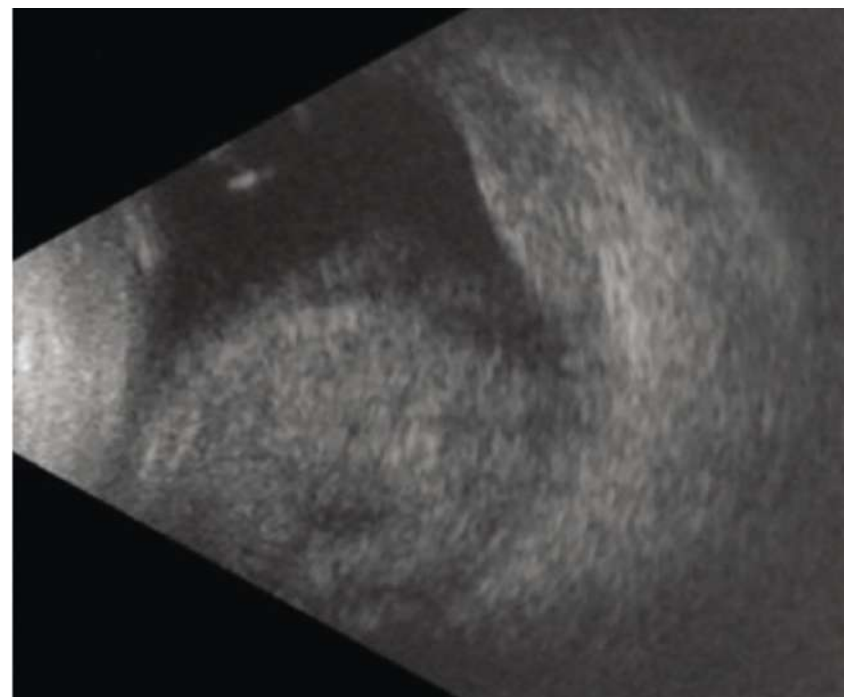
and IOP in the 30s. The exam showed mild hyphema, aphakia, large non-kissing hemorrhagic choroidals, and flat, but corrugated, retina (**Figure 1**).

We counseled the patient as to the guarded visual prognosis, the need for intense medical therapy and frequent follow-ups, as well as the need to wait 1 to 2 weeks for the clotted hemorrhage to liquefy before pursuing surgery to drain the SCH. We started him on topical atropine, max IOP-lowering drops, oral acetazolamide (Diamox Sequels, Teva Pharmaceuticals USA), and topical and oral steroids.

Over time, we saw consistent improvement symptomatically and on exam, so we canceled surgery and continued following him closely while slowly tapering him off of the medications. Once we deemed him stable enough for secondary IOL placement, an uneventful surgery took place to insert an anterior chamber intraocular lens around 9 months after presentation. He was last seen around 1 year after presentation, and everything looked fantastic: He had a VAsc of 20/70 (PH 20/40) and IOP 14 in his left eye. The retina was flat with peripheral pigmentary changes and rows of circumferential choroidal fold lines, and OCT showed a flat macula with mild ERM, ellipsoid zone changes, and improving choroidal folds (**Figure 2**).

### CASE EXAMPLE 2

A 73-year-old female experienced an expulsive choroidal hemorrhage in her right eye during topical cataract surgery after having sudden, severe coughing during phacoemulsification. A PC tear occurred, necessitating an anterior vitrectomy and sulcus IOL placement, at which point a suprachoroidal hemorrhage was noted. At clinic the same day, the patient noted significant eye pain alongside hand motion visual acuity and an IOP of 11. There were large hemorrhagic non-kissing choroidals, a vitreous



**FIGURE 3:** B scan of the right eye on presentation showing dense non-kissing choroidal hemorrhages, vitreous hemorrhage, and a flat retina.

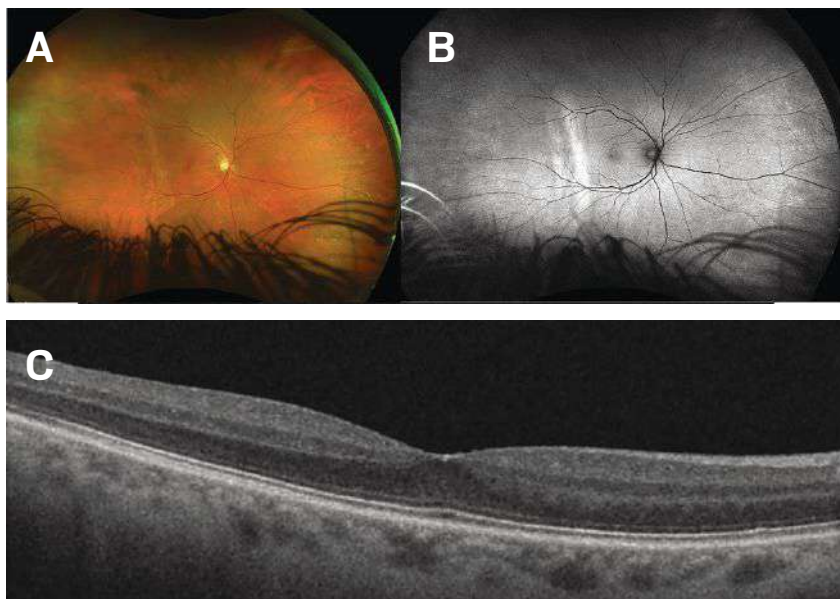
hemorrhage, and a flat retina best appreciated by B scan (**Figure 3**). Medical management similar to Case 1 was employed with close follow up.

After 3 weeks of close monitoring and medical treatment, the patient reported improved vision with a VAsc of 20/50 (PH 20/30). Four months after presentation, the patient was tapered off meds. Her clinical findings at that time: VAsc of 20/20, well-centered sulcus IOL, resolved vitreous hemorrhage and choroidal hemorrhages, and the retina remained flat.

### DISCUSSION

Postoperative management of SCH traditionally necessitated surgical intervention consisting of choroidal drainage with or without pars plana vitrectomy.<sup>3</sup> Surgical management with various techniques has been reported to





**FIGURE 3:** Multimodal imaging of the right eye at post-op month 4 visit: (A) Optos color fundus photo; (B) Optos autofluorescence revealing the subtle past resolved choroidal fold lines temporally; (C) OCT 5-line raster scan of the macula depicting a normal-appearing macula.

successfully restore vision in patients that could otherwise result in phthisis or severe loss of vision if left untreated.<sup>9,10</sup>

However, the optimal time for surgical intervention post incidence has not yet been definitively set. Previous studies have found that the optimal time for surgical intervention may be around 10 to 14 days after SCH occurrence.<sup>10</sup> This is due to the previous observation that drainage of an acute SCH creates an outflow that decreases the speed of thrombus liquefaction.<sup>11</sup> Additionally, posterior sclerotomy performed to evacuate blood in the suprachoroidal space and lower the IOP has proven to paradoxically result in a much larger choroidal hemorrhage resulting in vitreous hemorrhage, hyphema, and a worsening rise in IOP. This is theorized by the observation that elevated IOP from SCH may provide a protective tamponading effect against further bleeding, which is lost when the hemorrhage is drained too quickly in the acute event window.<sup>10,12</sup> Thus, in most cases, drainage is indicated when the suprachoroidal clot has shown signs of liquefaction on B scan ultrasonography around the 2-week mark.

However, not all SCHs may require surgical intervention. Cases with vitreous hemorrhage, vitreous incarceration, kissing choroids, or retinal tears/detachments have been reported to generally require surgical treatment, while mild, non-appositional SCHs may be observed to resolve spontaneously.<sup>7,13-14</sup> Here we described 2 cases of intraoperative phaco-related SCH that were successfully managed medically without a need for surgical intervention.

Case 1 involved a hypertensive 75-year-old man on long-term NSAID-medication, while case 2 involved a

73-year-old woman who coughed significantly intraoperatively. Both patients had severe non-kissing SCH with marked painful vision loss. Prompt medical management with topical and oral steroids, cycloplegics, IOP-lowering drops, and acetazolamide are necessary to begin as soon as possible. It took patience and confidence to forego surgery and to continue to carefully monitor the slowly improving SCH cases.

Therefore, suprachoroidal hemorrhage cases, although rare, can be managed on a case-by-case basis in which medical treatment, patience, and time can sometimes prove sufficient without the traditional need for surgery after 2 weeks. This conservative approach is an important option to consider, if the option is available, as surgical repair of SCH is often complex with a higher risk of complications. While there is need for frequent monitoring and medication adjustments for the nonsurgical approach, the end result can be a perfect 20/20-seeing eye. **NRP**

#### REFERENCES

- Eriksson A, Koranyi G, Seregard S, Philipson B. Risk of acute suprachoroidal hemorrhage with phacoemulsification. *J Cataract Refract Surg.* 1998;24(6):793-800.
- Chu TG, Green RL. Suprachoroidal hemorrhage. *Surv Ophthalmol.* 1999;43(6):471-486.
- Laube T, Brockmann C, Bornfeld N. Massive suprachoroidal hemorrhage: surgical management and outcome. *GMS Ophthalmol Cases.* 2015;5:Doc10.
- Davison JA. Acute intraoperative suprachoroidal hemorrhage in extracapsular cataract surgery. *J Cataract Refract Surg.* 1986;12(6):606-622.
- Weiss A, Henry C, Flynn Jr H. Observational management of suprachoroidal hemorrhage. *Retinal Physician.* 2014;11(4):47-51.
- Ling R, Cole M, James C, Kamalarajah S, Foot B, Shaw S. Suprachoroidal haemorrhage complicating cataract surgery in the UK: epidemiology, clinical features, management, and outcomes. *Br J Ophthalmol.* 2004;88(4):478-480.
- Reynolds MG, Haimovici R, Flynn HW Jr, DiBernardo C, Byrne SF, Feuer W. Suprachoroidal hemorrhage. Clinical features and results of secondary surgical management. *Ophthalmology.* 1993;100(4):460-465.
- Welch JC, Spaeth GL, Benson WE. Massive suprachoroidal hemorrhage. Follow-up and outcome of 30 cases. *Ophthalmology.* 1988;95(9):1202-1206.
- Lavinsky F, Moisseiev J, Levkovich-Verbin H. The surgical management of massive intraoperative and postoperative suprachoroidal hemorrhage: anatomic and functional outcomes. *Arq Bras Oftalmol.* 2013;76(4):212-214.
- Lakhanpal V, Schocket SS, Elman MJ, Dogra MR. Intraoperative massive suprachoroidal hemorrhage during pars plana vitrectomy. *Ophthalmology.* 1990;97(9):1114-1119.
- Wolter JR. Expulsive hemorrhage during retinal detachment surgery. A case with survival of the eye after Verhoeff sclerotomy. *Am J Ophthalmol.* 1961;51:264-266.
- Wirostko WJ, Han DP, Mieler WF, Pulido JS, Connor TB Jr, Kuhn E. Suprachoroidal hemorrhage: outcome of surgical management according to hemorrhage severity. *Ophthalmology.* 1998;105(12):2271-2275.
- Meier P, Wiedemann P. Massive suprachoroidal hemorrhage: secondary treatment and outcome. *Graefes Arch Clin Exp Ophthalmol.* 2000;238(1):28-32.
- Ruderman JM, Harbin TS, Campbell DG. Postoperative suprachoroidal hemorrhage following filtration procedures. *Arch Ophthalmol.* 1986;104(2):201-205.

**MR. LAI** is medical student at the University of Maryland School of Medicine, Department of Ophthalmology, in Baltimore, MD.

**DR. ELMAN** is the founding physician of Elman Retina Group, in Baltimore, MD.

**DR. SCHECHET** is in practice at Elman Retina Group, where he specializes in surgical and medical care of retinal and vitreous diseases.



# Predicting Outcomes Following Epiretinal Membrane Peeling Surgery

Macular anatomy may provide a clue to surgical outcomes

BY ZACK OAKEY, MD

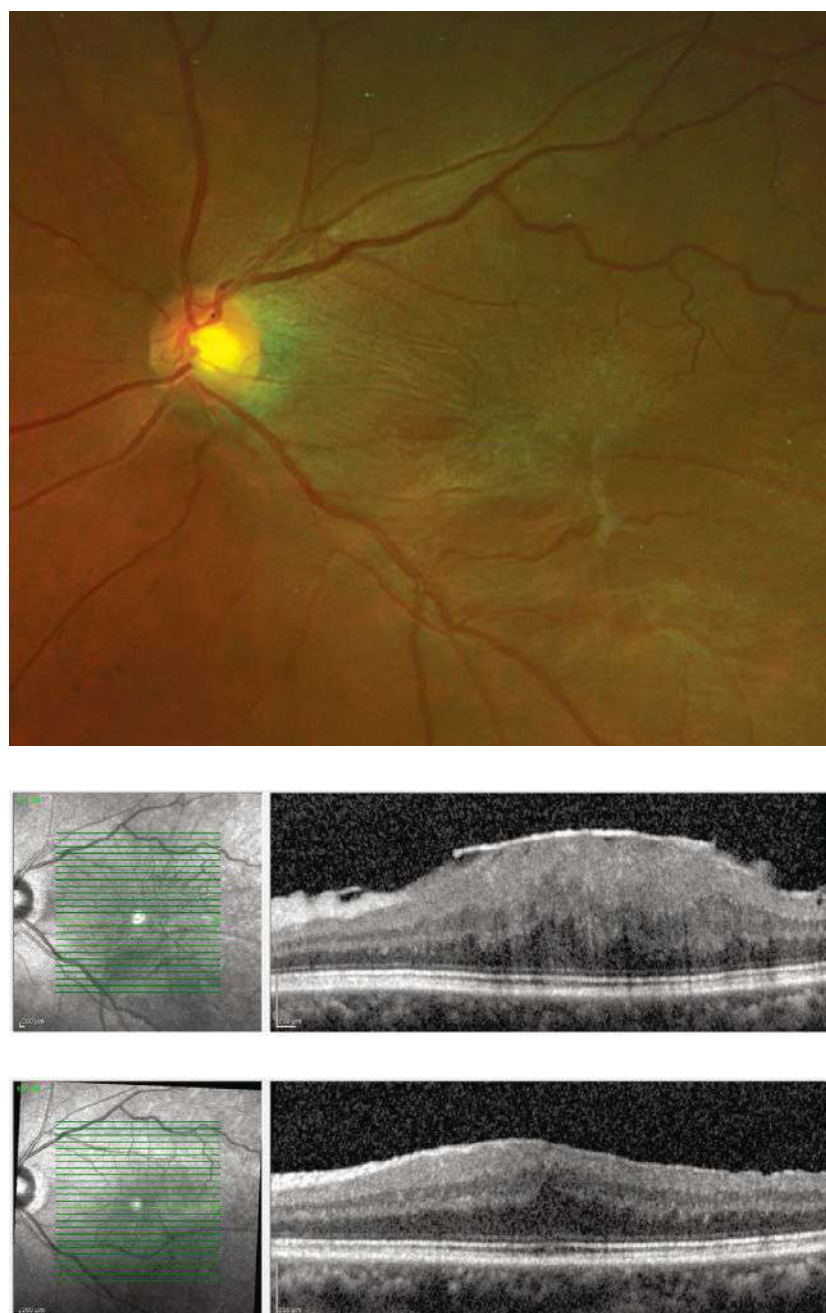
**T**he idiopathic epiretinal membrane (ERM) is a semitranslucent, glial, fibrocellular membrane that forms on the inner surface of the internal limiting membrane (ILM) at the macula.

It is present in as many as 35% of adults over age 65 without any pre-existing comorbid retinopathy.<sup>1</sup> It has been studied extensively, both in its epidemiological aspects and pathophysiologic mechanisms. The first documented surgery to remove an ERM was performed by Machemer in 1978.<sup>2</sup> And, although many questions remain as to its causation, understanding outcomes has been a larger subject.

As the number of intraocular surgeries (per 1,000 individuals) increases—advancements in surgical technology allow for surgery in cases for which ERM was previously not indicated—so too do the concerns over surgical outcomes.<sup>3</sup> As many as 10% of all vitrectomy surgeries performed in the United Kingdom are for an ERM indication (**Figure 1**).<sup>4</sup> Results vary from patient to patient, so it remains a challenge to set universal post-treatment visual expectations for patients in confounder-free cases where refraction and media have been adequately addressed.

Cohort studies have shown that visual function and retinal anatomy improve with surgical removal (**Figure 1**).<sup>5,6</sup> However, the timing of the surgery is an important element. Nearly a quarter will regress over time, but for the majority of patients, their condition either remains unchanged or worsens.<sup>7</sup>

The way in which ERM influences visual function and how those functional and clinical features tend to predict surgical outcomes has also been widely studied. Prior to the advent of optical coherence tomography (OCT), researchers found that if visual function was worse, the magnitude of improvement was greater after surgery.<sup>8</sup> Yet, Snellen acuity and assessing a patient's Amsler grid are



**FIGURE 1:** An idiopathic epiretinal membrane (ERM) that appears almost translucent on the inner surface of the internal limiting membrane (ILM) at the macula. Top: Color fundus photograph demonstrating incoherent retinal surface anatomy. Bottom: Optical coherence tomography cross-sectional image demonstrating a hyper-reflective lesion on the retinal surface with internal disorganization and thickening of the macula and fovea. Following removal, the individual layers of the retina are now more organized and vision is improved.

merely part of the whole in today's clinical setting. Knowing various anatomic features of the patient's retina may play an important role in predicting outcomes, and has been the subject of some study since the widespread use of OCT.

### OUTER RETINAL CHARACTERISTICS

Some of the first forays into using OCT as an attempt to predict outcomes came in the form of evaluating the outer retina. In a 2012 study, Kim and colleagues found that if the inner segment/outer segment (IS/OS) was not readily identifiable or disrupted prior to surgery, mean final best-corrected visual acuity (BCVA) was 0.64 (logMAR, approximately 20/100 Snellen) in the disrupted group and 0.07 (logMAR, approximately 20/20 Snellen) in the intact group 12 months after surgery (accounting for media opacity and refractive error).<sup>9</sup>

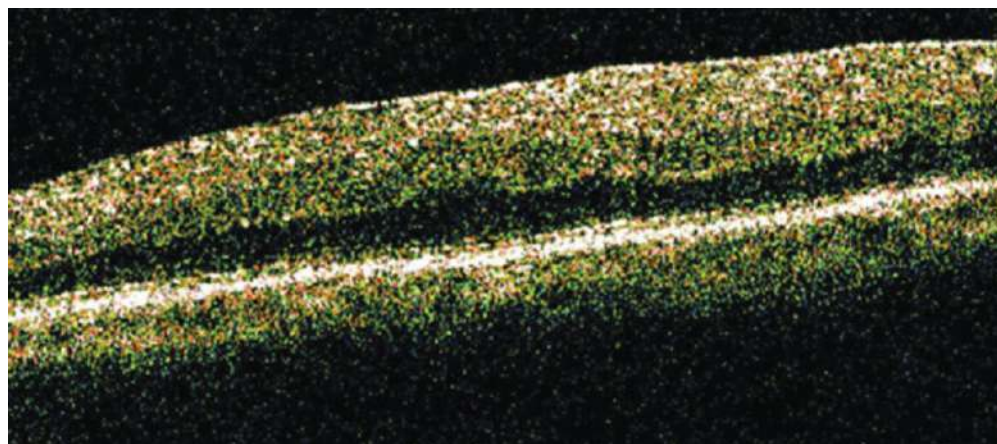
**Figure 2** demonstrates such an example.

However, the magnitude of visual gain in each respective group was not different, although the final results differed.<sup>9</sup> Similar findings were replicated by Shimozono et al., who made further attempts using spectral-domain OCT to discern any differences when evaluating those with an intact IS/OS but attenuated cone outer segment tips (COST).<sup>10</sup>

They found that patients experienced earlier gains when IS/OS and COST were intact, as compared with intact IS/OS but attenuated COST. However, this difference was not present by 6 months. Ultimately, they found IS/OS was the dependent variable, reproducing the work of Kim et al.<sup>9,10</sup>

Because Shimozono could not find enough enrollees to determine whether external limiting membrane (ELM) attenuation was a dependent variable, Watanabe and others presented an analysis in which ELM was included, showing that COST derangement was an important longitudinal variable in addition to IS/OS and ELM.<sup>11</sup> Those patients evaluated by Watanabe did not undergo surgery, therefore one cannot predict these findings' contribution to surgical outcomes in a post hoc analysis. Some consider this finding predictive, but in the absence of direct comparison, knowing the ELM's independent contribution may be only inferred.

Based on the above work, it appears that to the extent that the inner and outer segments, cone outer segments, and ELM are affected by an ERM, the worse acuity will be over time, and may predict worse acuity outcomes.



**FIGURE 2:** Optical coherence tomography image presented by Kim et al. demonstrating an example case in which attenuated IS/OS is present even without significant thickening and internal disorganization.

### MACULAR THICKENING

In addition to IS/OS and COST changes, overall macular thickening has been identified as a potential predictor of worse outcomes, whether or not enervation to IS/OS or COST are found. In a review in which 101 eyes underwent surgery, the average presurgical thickness was 426  $\mu\text{m}$  and was reduced to 321  $\mu\text{m}$ .<sup>12</sup> There was a significant improvement in BCVA and metamorphopsia over the 6 month postoperative period only in those eyes in which the macula was relatively thick and there was no identified loss of IS/OS on OCT. Authors found macular thickness was supplanted in its predictive value by implied injury to the IS/OS.

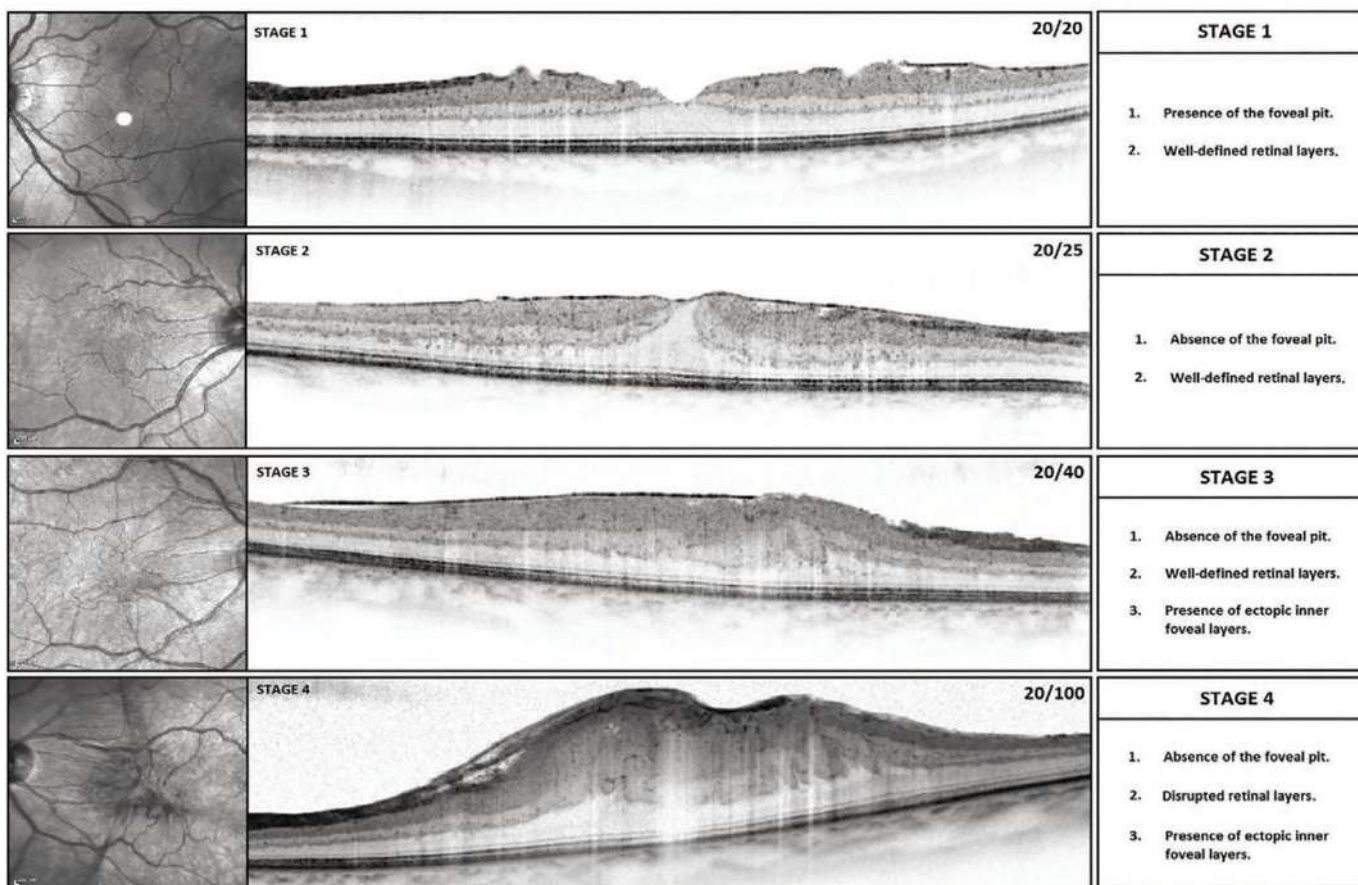
Seeming to contradict this finding, Massin and colleagues published a study of 62 eyes with 22-month average follow-up stating that average macular thickness did not correlate well with outcomes.<sup>13</sup> This was published in 2000, prior to the advent of spectral-domain OCT, and most patients were evaluated using low-resolution B scan images. For example, the authors stated that it was difficult to find an ERM because the growth “was seen in only 42% of cases,” and more visible when the membrane was “slightly separated from the underlying retina” and that “it was difficult to differentiate...from the normal backscattering of the optic nerve fiber layer.”<sup>13</sup> However, as OCT technology has advanced significantly through the years, this experience was later contradicted by a 1996 study showing a different relationship that has been reproduced.<sup>14-16</sup>

Macular thickness may be another factor in determining outcomes. It may be that the thicker the overall macula is, the worse the outcome in surgery.

### ECTOPIC INNER FOVEAL LAYER

As the study of ERM has evolved, other features within





**FIGURE 3:** Series of optical coherence tomography images demonstrating a proposed staging scheme in which finally by Stage 3 there are ectopic inner layers within the middle retina. Note that the INL and IPL have entered the umbo where they are typically not found in age-matched normal retinal layers and in Stage 1 and Stage 2.

the middle retina have been identified as potential predictors of outcomes, namely an ectopic inner foveal layer. Govetto and colleagues noted that in the more progressed stages, in which other elements, such as thickening and IS/OS attenuation, may or may not occur, layers within the retina showed communication independently.<sup>17</sup> They found that the inner nuclear layer (INL) and inner plexiform layer (IPL) in particular seemed to demonstrate mobility or invasion into other inner retinal compartments where they are not normally found (**Figure 3**). Govetto et al. constructed a grading scheme, while accounting for outer retinal changes previously noted.<sup>17</sup>

In this scheme, Stage 1 is when the macula shows the presence of an ERM, yet the normal retinal layers are discrete—particularly that the outer nuclear layer (ONL) spans the central fovea. As stages progressed, the INL and IPL mobilized centrally, covering the ONL. This was described as ectopic, given that only the ONL is normally present over the fovea, with the INL and IPL tapering and eventually becoming absent over the umbo. By Stage 3, the layers of the retina are distinct, but the INL and IPL have covered the ONL and umbo. Stage 4 occurs when there is an ectopic INL and IPL, and layers are no longer distinct.

Using this system, the authors found that the further a patient progressed—even identifying that IS/OS and COST were intact and the foveal avascular zone showed preserved perfusion—vision was degraded. The authors felt that an ectopic inner foveal layer, based on multivariate linear regression, was an independent risk factor for vision loss. One unfortunate feature of this work is that there was no

pre- or postsurgical analysis. Therefore, we await post hoc correlation.

In short, aside from outer layer interruption and overall thickening, middle retinal characteristics may be predictive for surgical outcomes. Similar to some studies describing ELM contribution, this is merely theoretical until a well-designed intention to treat study can be conducted with perioperative comparisons.

## CONCLUSION

Since the advent of OCT, anatomic features have been studied in ERM and have been found to be useful in predicting surgical outcomes in several instances. History, physical exam findings, and measured acuity still serve as the foundation in the overall assessment of predicted outcomes, but more clarity in the form of anatomic studies have added to predictive capabilities.

Particular elements of the internal anatomy of the macula, including IS/OS, COST, and ELM attenuation, overall thickening, and the presence of an ectopic inner foveal layer, have been shown to either correlate with worse acuity or worse predicted surgical outcomes (**Table 1**). Still, much work is needed to understand the pre- and postsurgical outcomes. **NRP**

## REFERENCES

1. Klein R, Klein BE, Wang Q, Moss SE. The epidemiology of epiretinal membranes. *Trans Am Ophthalmol Soc.* 1994;92:403-430.

CONTINUED ON PAGE 19



# Surgical Techniques to Remove Subretinal Perfluoro-n-Octane

## An examination of benefits and risks

BY RAZIYEH MAHMOUDZADEH, MD; SAMIR N. PATEL, MD; CARL D. REGILLO, MD; DONALD J. D'AMICO, MD; AND AJAY E. KURIYAN, MD, MS

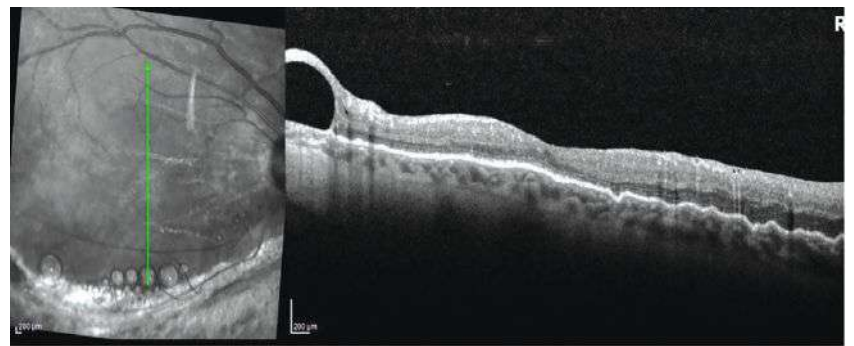
**P**erfluorocarbon liquids (PFCL) have high specific gravity and optical clarity, which permit intraoperative retinal tissue manipulation. Perfluoro-n-octane (PFO; C<sub>8</sub>F<sub>18</sub>; Perfluron, Alcon) has the most visible interface among other types of PFCL, which helps to have the best intraoperative removal rate.<sup>1</sup> Generally, PFCLs have a postoperative subretinal retention rate of 0.9% to 11.1%, with a lower rate for PFO being in the 1% to 3.5% range.<sup>2,3</sup> Risk factors for subretinal retention are large retinotomy of 120 degrees or more and failure to perform a saline rinse after fluid-air exchange.<sup>2</sup>

### WHY REMOVAL IS VITAL

Pastor et al. showed that PFO has a toxic effect on the human retinal pigment epithelial (RPE) cells (ARPE-19).<sup>4</sup> Elsing et al. also showed that histopathologic analysis of five eyes with retained PFO after vitreoretinal surgery for retinal detachment revealed an inflammatory response.<sup>5</sup> This inflammatory response consisted mainly of macrophages with intracellular vacuoles containing PFO. However, removal of the PFO in all five eyes resulted in the resolution of the inflammatory response.<sup>5</sup> Given the toxic effect of PFO on RPE and loss of retinal functions, subfoveal or sub-juxtafoveal PFO is often removed.<sup>6</sup> However, sub-extramacular or subperipheral retina PFO does not result in a negative functional or anatomical outcome, and may be safely left alone<sup>2</sup> (Figure 1).

### REMOVAL TECHNIQUES

**Direct aspiration.** Several techniques have been described to remove the submacular PFO. One common approach is direct aspiration using a small gauge



**FIGURE 1:** Subperipheral macula PFO which was managed by observation only.

(36-gauge or smaller) that is passed through the retina into the subfoveal space. The aspiration can be performed manually or via the extrusion line to enable foot pedal control.<sup>7-10</sup> However, this method can damage the RPE and photoreceptors, and cause vision-threatening complications, such as choroidal neovascular membrane, macular hole, or submacular hemorrhage.<sup>11</sup>

**Removal through slit.** To minimize these risks, another method utilizes a 25-gauge microvitrectomy (MVR) blade to create a small full-thickness slit above the PFO bubble, followed by the use of a soft-tip cannula to massage the subretinal PFO through the slit and displace it from the subretinal space.<sup>12</sup>

**Transretinal aspiration.** Another technique eliminates the need for any entry through the retina, but instead utilizes a 23- or 25-gauge silicone-tip cannula placed right above the retina overlying the subretinal PFO to aspirate the PFO transretinally with passive or active aspiration<sup>13</sup> (Figure 2).

**Displacement.** Another technique that attempts to minimize the potential risks of direct aspiration of the PFO involves displacing the subfoveal PFO to a more peripheral location prior to removal. In this approach, a temporary therapeutic retinal detachment is created

by injecting balanced saline solution into the subretinal space using a small-gauge cannula (36-gauge or smaller) in the peripheral macula.<sup>14</sup> This detachment should involve the entire macula (or beyond) to allow the subfoveal PFO droplet to move peripherally.

A few different methods can be utilized to manage the PFO droplet once it has moved away from the subfoveal location. One technique is to remove the displaced subretinal PFO using direct aspiration through the retina using a small-gauge cannula (36-gauge or smaller). Another technique is to make a small retinotomy just outside the macula through which to aspirate the subretinal PFO and balanced salt solution (BSS). Displacement of the PFO toward an inferior retinotomy may be aided by intraoperative patient head elevation and vibration.<sup>15</sup>

If the PFO has been displaced sufficiently peripherally, a technique of not removing the subretinal BSS and allowing the RPE to reabsorb the BSS has also been described in a patient—the subretinal PFO remained in a more peripheral location. One potential complication of this method is injecting the BSS at high pressure, which may rupture the thinned foveal neuroepithelium and create a full-thickness macular hole or cause RPE atrophy.<sup>14</sup>

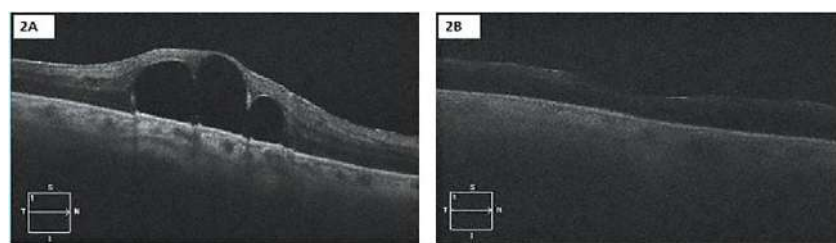
Kim et al. described two cases of surgical removal of subfoveal PFCL through a subretinal BSS injection-induced macular hole, which subsequently closed with gas tamponade.<sup>16</sup>

## CONCLUSION

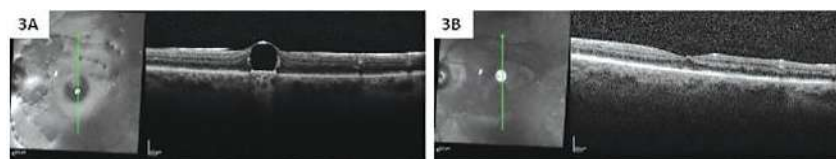
Although surgical removal of retained submacular PFCL can improve vision and improve the secondary central scotoma, decreased vision or loss of retinal sensitivity does not necessarily indicate the need for surgery.<sup>17</sup> Many patients with submacular PFCL have limited visual potential secondary to their retinal detachments, and the potential benefits and risks must be discussed with the patient.<sup>11,18</sup> If the decision is made to remove centrally located submacular PFCL, the surgery is best performed within several weeks of detection to get the best potential visual outcome. **NRP**

## REFERENCES

1. Crafoord S, Larsson J, Hansson LJ, Carlsson JO, Stenkula S. The use of perfluorocarbon liquids in vitreoretinal surgery. *Acta Ophthalmol Scand*. 1995;73(5):442-445.
2. Garcia-Valenzuela E, Ito Y, Abrams GW. Risk factors for retention of subretinal perfluorocarbon liquid in vitreoretinal surgery. *Retina*. 2004;24(5):746-752.
3. Bourke RD, Simpson RN, Cooling RJ, Sparrow JR. The stability of perfluoro-n-octane during vitreoretinal procedures. *Arch Ophthalmol*. 1996;114(5):537-544.
4. Pastor JC, Coco RM, Fernandez-Bueno I, et al. Acute retinal damage after using a toxic



**FIGURE 2:** The submacular PFO was aspirated transretinally using a soft-tip cannula. Before surgery (A) vs. postsurgery (B).



**FIGURE 3:** The submacular PFO was removed with subretinal BSS injection and PFO removal through induced macular hole. Before surgery (A) vs. postsurgery (B).

- perfluoro-octane for vitreo-retinal surgery. *Retina*. 2017;37(6):1140-1151.
5. Elsing SH, Fekrat S, Green WR, Chang S, Wajer SD, Haller JA. Clinicopathologic findings in eyes with retained perfluoro-n-octane liquid. *Ophthalmology*. 2001;108(1):45-48.
  6. Saatci AO, Koçak N. Retained submacular perfluorodecalin. *Can J Ophthalmol*. 2003;38(4):293-296.
  7. Lai JC, Postel EA, McCuen BW. Recovery of visual function after removal of chronic subfoveal perfluorocarbon liquid. *Retina*. 2003;23(6):868-870.
  8. García-Arumí J, Castillo P, López M, Boixadera A, Martínez-Castillo V, Pimentel L. Removal of retained subretinal perfluorocarbon liquid. *Br J Ophthalmol*. 2008;92(12):1693-1694.
  9. Roth DB, Sears JE, Lewis H. Removal of retained subfoveal perfluoro-n-octane liquid. *Am J Ophthalmol*. 2004;138(2):287-289.
  10. Joondeph BC. Controlled aspiration of subfoveal perfluorocarbon liquid using a novel micro-cannula. *Retina*. 2011;31(5):991-993.
  11. Lesnoni G, Rossi T, Gelso A. Subfoveal liquid perfluorocarbon. *Retina*. 2004;24(1):172-176.
  12. Charles S. Intracacies of the Use Of Perfluorocarbon Liquids. *Retinal Physician*. 2012;9(Oct):61-61.
  13. Erden B, Erdenöz S, Çakır A, Bölükbaşı S, Elçioğlu M. Direct transretinal removal of subfoveal perfluorocarbon liquid combined with internal limiting membrane peeling. *Ther Adv Ophthalmol*. 2019;11:2515841419840244.
  14. Le Tien V, Pierre-Kahn V, Azan F, Renard G, Chauvaud D. Displacement of retained subfoveal perfluorocarbon liquid after vitreoretinal surgery. *Arch Ophthalmol*. 2008;126(1):98-101.
  15. Takahashi K, Kimura S, Hosokawa MM, et al. Release and extraction of retained subfoveal perfluorocarbon liquid facilitated by subretinal BSS, vibration, and gravity: a case report. *BMC Ophthalmol*. 2020;20(1):427.
  16. Kim JM, Woo SJ, Park KH, Chung H. Surgical removal of retained subfoveal perfluorocarbon liquid through a therapeutic macular hole with intravitreal PFCL injection and gas tamponade. *Korean J Ophthalmol*. 2013;27(5):392-395.
  17. Tewari A, Elliott D, Singh CN, Garcia-Valenzuela E, Ito Y, Abrams GW. Changes in retinal sensitivity from retained subretinal perfluorocarbon liquid. *Retina*. 2009;29(2):248-250.
  18. Suk KK, Flynn HW. Management options for submacular perfluorocarbon liquid. *Ophthalmic Surg Lasers Imaging*. 2011;42(4):284-291.

**RAZIYEH MAHMOUDZADEH, MD**, is a postdoctoral research fellow at Wills Eye Hospital in Philadelphia.

**SAMIR N. PATEL, MD**, is affiliated with Wills Eye Hospital, Mid Atlantic Retina, and Thomas Jefferson University in Philadelphia.

**CARL D. REGILLO, MD, FACS**, is chief of the Retina Service at Wills Eye Hospital.

**DONALD J. D'AMICO, MD**, is a professor and chairman of Ophthalmology at Weill Cornell Medical College and ophthalmologist-in-chief at the New York Presbyterian Hospital, both in New York City.

**AJAY E. KURIYAN, MD, MS**, is an active member of the Retina Service at Wills Eye Hospital, and is an associate professor of ophthalmology at Sidney Kimmel Medical College of Thomas Jefferson University.

# Social Networking

How to leverage social media to promote your retina practice

BY DAVID R.P. ALMEIDA, MD, MBA, PHD

**S**ocial media is a ubiquitous element of modern life. Although retina practices are traditionally conservative in their electronic communications, we are now beyond the tipping point of widespread social media use. Here, we will discuss how getting online can help bring patients into your practice—and boost your bottom line.

## BRANDING IS KEY

There is no successful path to practice promotion via social media without brand definition and awareness. The brand is the basis of the relationship between patient, client, or consumer, and the product or service (i.e., health care) consumed. You and your practice need a defined brand. If you don't have a brand identity, assess what is most important to you and your practice and where your strengths lie. If you do nothing else but crystalize your brand message, this review will be worthwhile.

Once you have established the tenets central to your practice, define the groups you want to reach via social media. Think of who your practice is trying to reach, such as patients and their family members, in addition to referring physicians. General ophthalmologists and other physicians need a retina practice in which they have confidence and one that makes it easy for them to refer their patients who are in need of retina care.

When it comes to content, the most straightforward and best promotional strategy is to focus on providing helpful information, such as patient resources and medical updates, including patient disease summaries (e.g., what is a retinal detachment?), procedure information (e.g., what to expect when you come in for an intravitreal injection), and topical medical updates (e.g., new product approvals or novel services offered in a respective practice).

In terms of frequency, practice promotion via social media is an ongoing, active pursuit that must evolve as your practice patterns change and your patient population grows. Think of your website and social media as moving vehicles, where a lack of updates can stagnate your effectiveness at reaching your target audience.

## SOCIAL MEDIA PLATFORMS

Retina practices can choose from an array of social media platforms. Facebook, Twitter, LinkedIn, and Instagram are all large-scale social media sites on which users can share images, post links, and communicate with other users. They are all great options to reach your target patient audience.

On the business side, Doximity is a specialized online social networking service for U.S. clinicians with a variety of functions, including contacts, professional profiles, continuing medical education, and a digital doctors

lounge for conversation. According to the company, the site has upwards of 1.8 million verified users, with more than 80% of U.S. doctors and 50% of all nurse practitioners and physician assistants as members.<sup>1</sup>

## WEB-BASED RATINGS

The advent of online and social medical platforms has democratized the ability to review and judge your delivery of medical care. More than 80% of all U.S. adults use online sites to inform their product or service purchase decisions.<sup>2</sup> Not surprisingly, health care is no different, with 53% of physicians and 39% of patients visiting a healthcare rating website at least once to evaluate a physician or practice.<sup>3</sup> The principal health-care rating sites include Google, RateMDs.com, HealthGrades.com, Vitals.com, and Yelp. Unfortunately, anyone can post to these sites, and verification remains a problem. Nonetheless, a strong brand and social media presence can help counterbalance any negative reviews.

## GETTING STARTED

Any of the major social media apps can be used as a gateway into online promotion. In my opinion, Twitter is a logical starting point. Think of it as your “micro-blog.” Your tweets allow you to highlight your practice and connect with colleagues, patients, and others in a short, easily digestible, and enjoyable format.



Tweeting doesn't require significant time or energy, and anyone can read tweets. Although only registered account holder can post tweets and comments, anyone with an internet connection can view your tweets. A record of all tweets is stored on your home page, which offers a summary of your practice.

### SOCIAL MEDIA PITFALLS TO AVOID

- **Violating Patient Privacy:** You cannot provide patient-specific information or images online. This violates patient privacy and has serious legal consequences. Do not, under any circumstance, post patient information without permission or use a social media platform to communicate directly with a patient about a specific medical problem. If a patient wants to communicate, you or your office should contact that patient directly by phone and move the discussion to a private phone call or an in-office visit.
- **Online Sales:** Be careful with selling products on your website. This has the potential for conflicts of interest, which can damage patient-physician and patient-practice relationships. For example, advertising a specific product (e.g., nutritional supplements) can create the optics of bias, and may be viewed negatively by patients and colleagues.
- **Infrequent updates:** Failure to regularly update your account will quickly lead to low visibility and hinder your ability to promote your practice. Be sure to keep your accounts active and your content relevant to your audience.

### CONCLUSIONS

Through the connectivity of affordable internet access and multiple online platforms, social media now contributes to the narrative in medicine and influences social commentary. Proactive promotion of your retina practice on social media allows you to have an active voice and offers you a direct line to your patients and referring physicians, as well as an online audience at large. **NRP**

### REFERENCES

1. Doximity website. 2021. Available at: <https://press.doximity.com/>. Last accessed Sept. 15, 2021.
2. Smith A, Anderson M. Pew Research Center. Online shopping and e-commerce. <http://www.pewinternet.org/2016/12/19/online-shopping-and-e-commerce/> Published December 19, 2016. Accessed November 28, 2018.
3. Holliday AM, Kachalia A, Meyer GS, Sequist TD. Physician and patient views on public physician rating websites: a cross-sectional study. *J Gen Intern Med.* 2017;32(6):626–631. doi:10.1007/s11606-017-3982-5

**DR. ALMEIDA** is in private practice at Erie Retinal Surgery and is director of clinical research at Erie Retina Research. He can be reached at [drpa@pm.me](mailto:drpa@pm.me).

### CONTINUED FROM PAGE 15

	WORSE VISION	WORSE SURGICAL OUTCOME
IS/OS attenuation	X	X
COST attenuation	X	X
ELM attenuation	X	
Thickening	X	X
Ectopic inner foveal layer	X	

**TABLE 1:** Patients who have been shown to have worse vision compared with those who do not demonstrate anatomic features listed. In the first column, studies conducted on ERM demonstrate those with findings listed tend to develop worse vision, however in the second column only some have undergone surgery in a systematic review and been found to have worse relative outcomes.

2. Machemer R. [The surgical removal of epiretinal macular membranes (macular puckers) (author's transl)]. *Klin Monbl Augenheilkd.* 1978; 173(1): 36–42.
3. Wubben TJ, Talwar N, Blachley TS, Gardner TW, Johnson MW, Lee PP, Stein JD. Rates of vitrectomy among enrollees in a united states managed care network, 2001–2012. *Ophthalmology.* 2016;123(3):590–598.
4. Jackson TL, Donachie PHJ, Sparrow JM, Johnston RL. United Kingdom national ophthalmology database study of vitreoretinal surgery: report 1; case mix, complications, and cataract. *Eye (Lond).* 2013;27:644–651.
5. Wong JG, Sachdev N, Beaumont PE, Chang AA. Visual outcomes following vitrectomy and peeling of epiretinal membrane. *Clin Exp Ophthalmol.* 2005;33(4):373–378.
6. Pournaras CJ, Emarah A, Petropoulos IK. Idiopathic macular epiretinal membrane surgery and ILM peeling: anatomical and functional outcomes. *Semin Ophthalmol.* 2011; 26(2): 42–46.
7. Fraser-Bell S, Guzowski M, Roctchina E, Wang JJ, Mitchell P. Five-year cumulative incidence and progression of epiretinal membranes: the Blue Mountains Eye Study. *Ophthalmology* 2003; 110(1): 34–40.
8. Tanikawa A, Shimada Y, Horiguchi M. Comparison of visual acuity, metamorphopsia, and aniseikonia in patients with an idiopathic epiretinal membrane. *Jpn J Ophthalmol.* 2018;62(3):280–285.
9. Kim JH, Kim YM, Chung EJ, Lee SY, Koh HJ. Structural and functional predictors of visual outcome of epiretinal membrane surgery. *Am J Ophthalmol.* 2012;153(1):103–10.e1
10. Shimozone M, Oishi A, Hata M, Matsuki T, Ito S, Ishida K, Kurimoto Y. The significance of cone outer segment tips as a prognostic factor in epiretinal membrane surgery. *Am J Ophthalmol.* 2012;153(4):698–704, 704.e1
11. Watanabe K, Tsunoda K, Mizuno Y, Akiyama K, Noda T. Outer retinal morphology and visual function in patients with idiopathic epiretinal membrane. *JAMA Ophthalmol.* 2013;131(2):172–177.
12. Suh MH, Seo JM, Park KH, Yu HG. Associations between macular findings by optical coherence tomography and visual outcomes after epiretinal membrane removal. *Am J Ophthalmol.* 2009;147(3):473–480.e3.
13. Massin P, Allouch C, Haouchine B, Metge F, Paques M, Tangui L, Erginay A, Gaudric A. Optical coherence tomography of idiopathic macular epiretinal membranes before and after surgery. *Am J Ophthalmol.* 2000;130(6):732–739.
14. Koo HC, Rhim WI, Lee EK. Morphologic and functional association of retinal layers beneath the epiretinal membrane with spectral-domain optical coherence tomography in eyes without photoreceptor abnormality. *Graefes Arch Clin Exp Ophthalmol.* 2012;250(4):491–498.
15. Song SJ, Lee MY, Smiddy WE. Ganglion cell layer thickness and visual improvement after epiretinal membrane surgery. *Retina.* 2016;36(2):305–310.
16. Cho KH, Park SJ, Cho JH, Woo SJ, Park KH. Inner-retinal irregularity index predicts postoperative visual prognosis in idiopathic epiretinal membrane. *Am J Ophthalmol.* 2016;168: 139–149.
17. Govetto A, Lalane 3rd RA, Sarraf D, Figueroa MS, Hubschman JP. Insights into epiretinal membranes: presence of ectopic inner foveal layers and a new optical coherence tomography staging scheme. *Am J Ophthalmol.* 2017;175:99–113.

**DR. OAKLEY** is a vitreoretinal surgeon with Pomona Valley and Arrowhead medical centers in Rancho Cucamonga, CA. He has no disclosures to report.

# See the retina from a **Safe Distance.**

- 200° single-capture
- Multi-mode
- Easy to clean

Optos helps you see and document the retina with no face-to-face interaction. **optomap**® single capture UWF imaging has been shown to increase practice flow and patient engagement.

**Keep your staff and patients safer with optomap**

Contact us today to put the power, efficiency and safety of **optomap** in your practice  
800-854-3039 [www.optos.com](http://www.optos.com)

